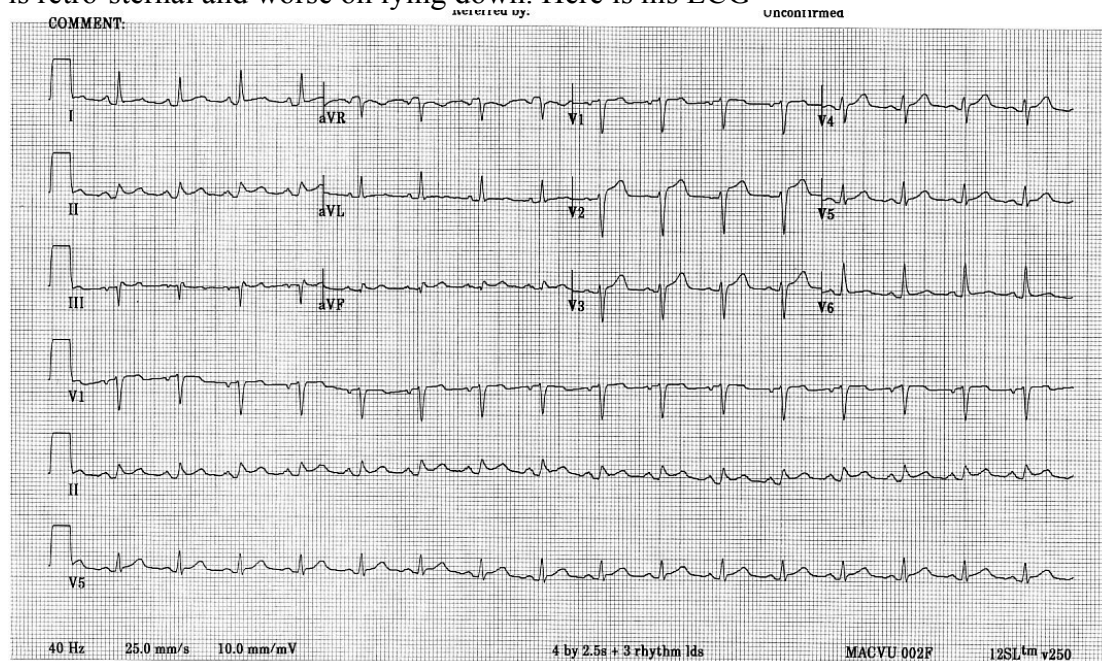


ECG young man

A 25 yr old man presents to your department with a 3 day history of chest pain, which is retro-sternal and worse on lying down. Here is his ECG



What is the diagnosis? 2 marks

Pericarditis

What features on the ECG are typical of this? 2 marks

Widespread mild ST elevation and PR depression

What is the treatment? 2 marks

Oxygen and cardiac monitoring

NSAIDS

Name 1 possible life-threatening complication 1 mark

Cardiac Tamponade

Give 3 possible causes 3 marks

Viral (PR depression in 80% of these)

SLE, RA

TB

Acute MI or Dresslers syndrome

<http://www.emedicine.com/EMERG/topic412.htm>

Asked Nov 2002