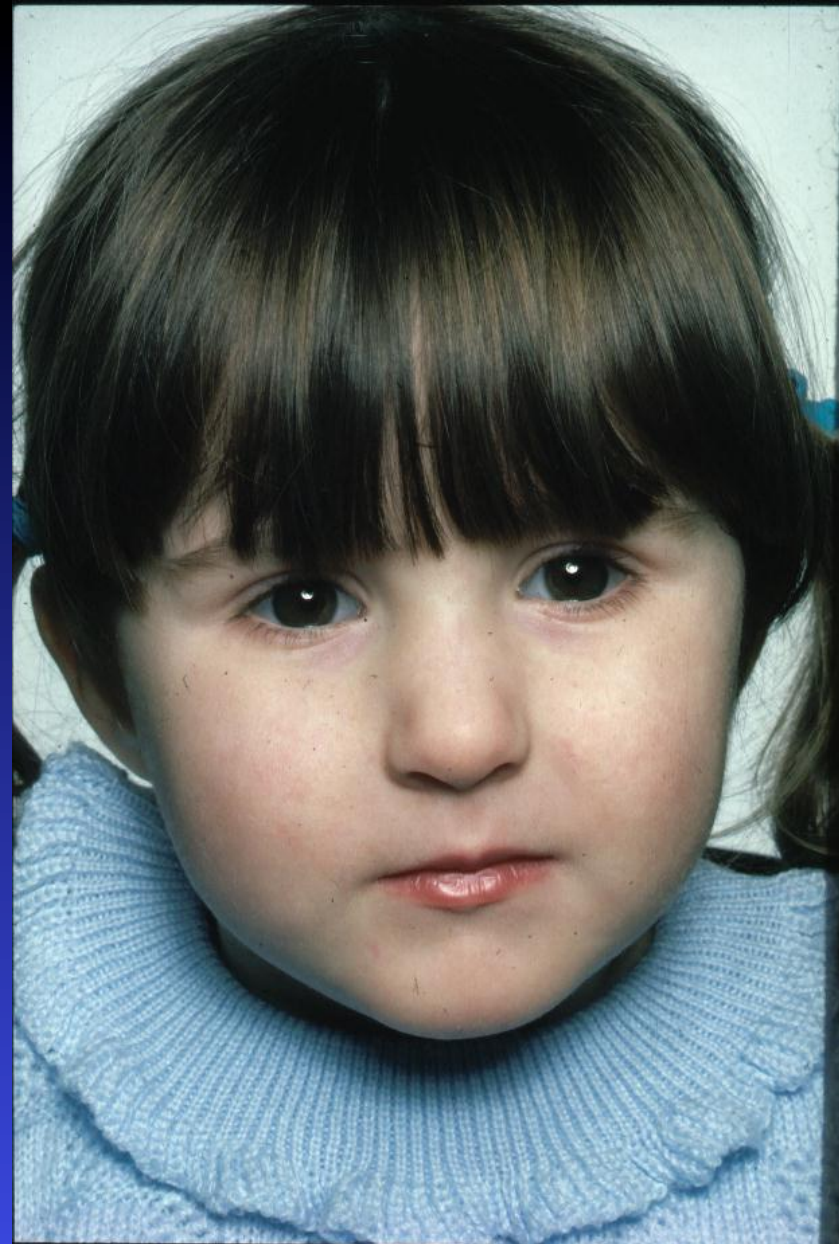
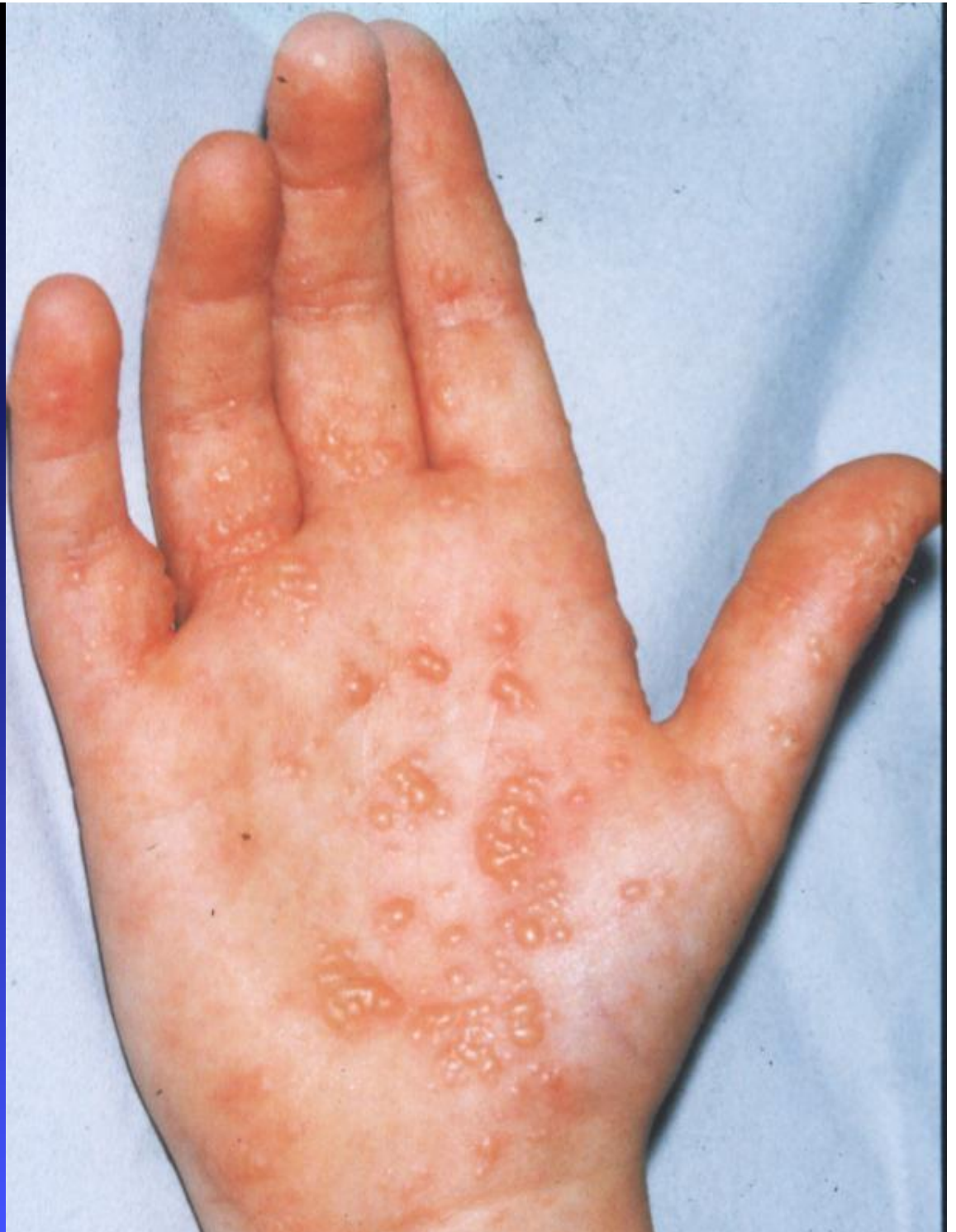


Picture Quiz 1

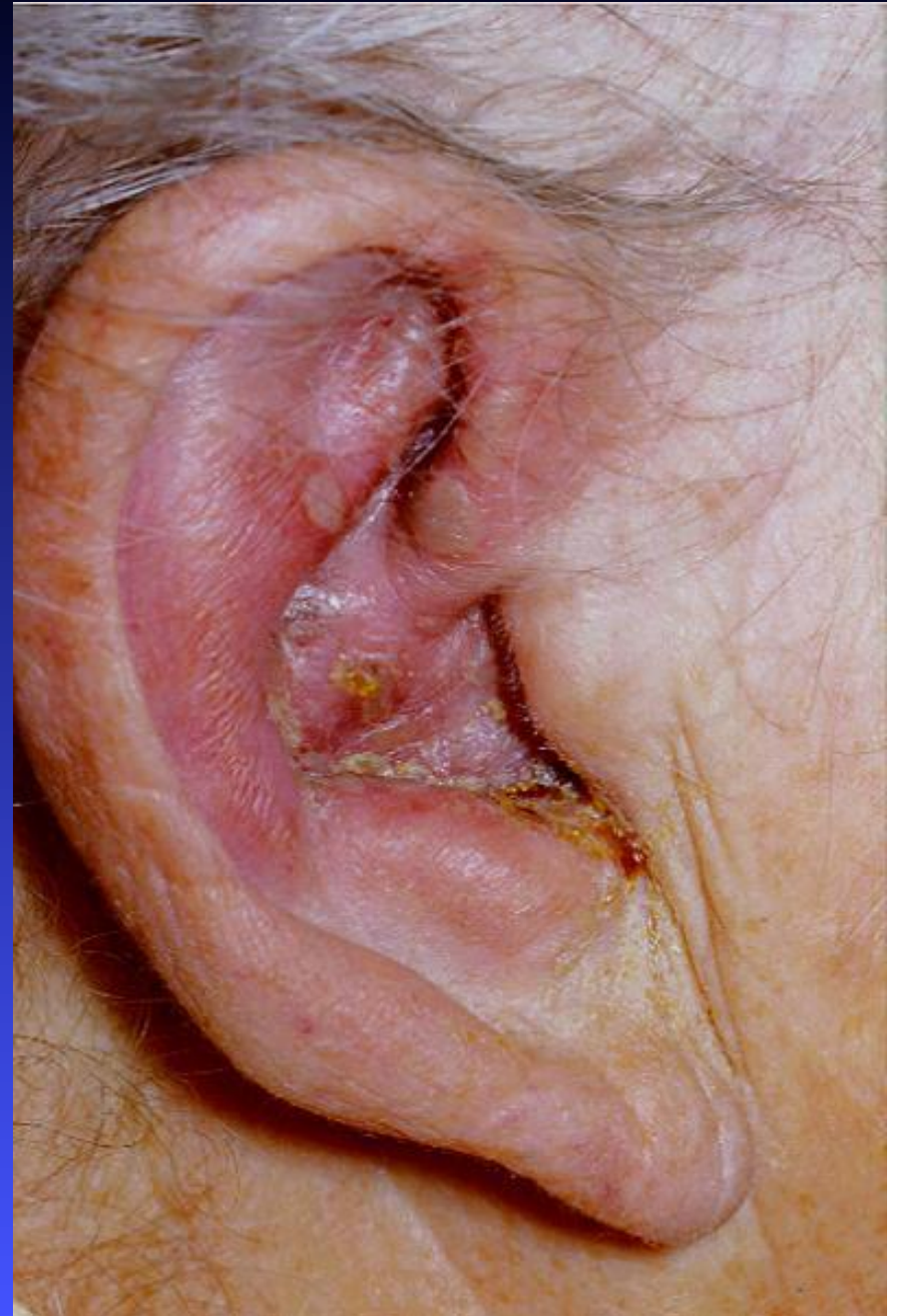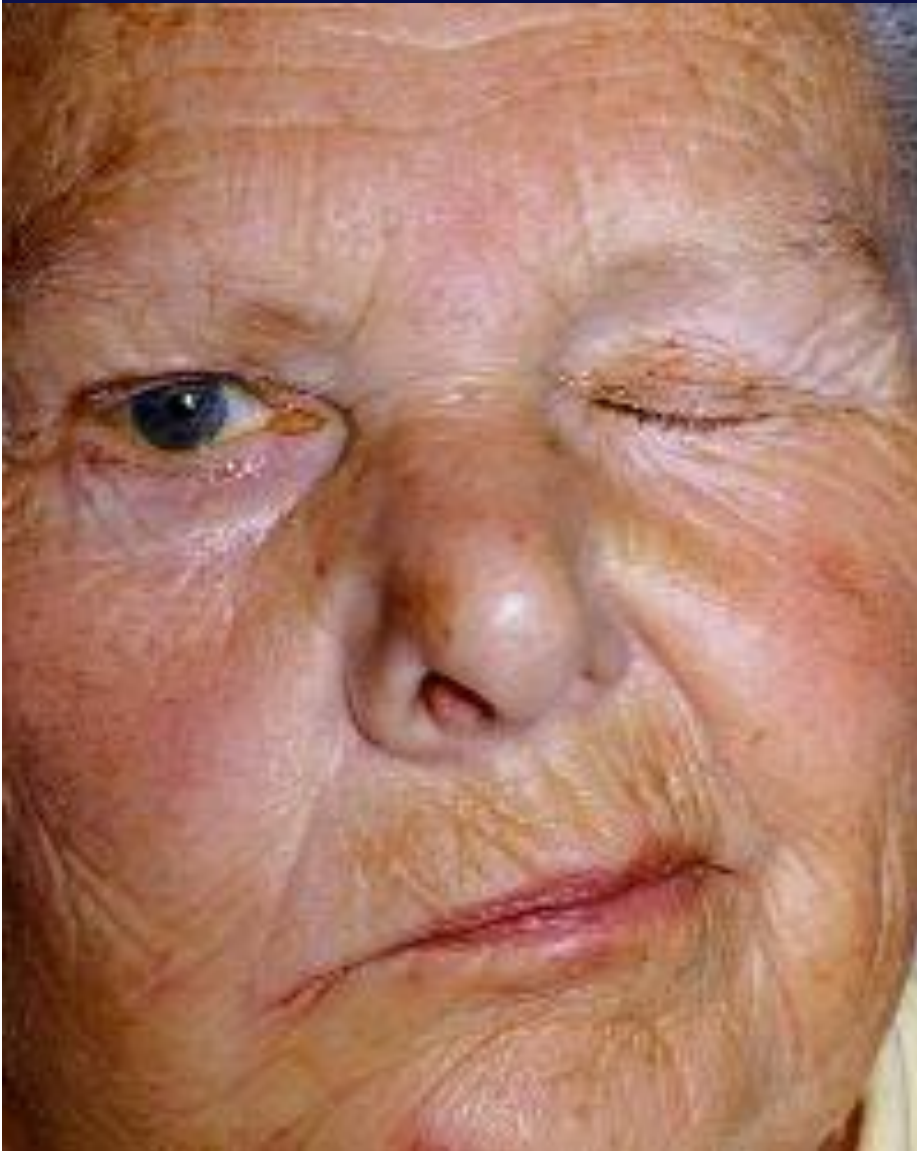1. Why has this child attended A&E several times with limb fractures ?
2. What specific abnormality would you find on examining the neurological system ?

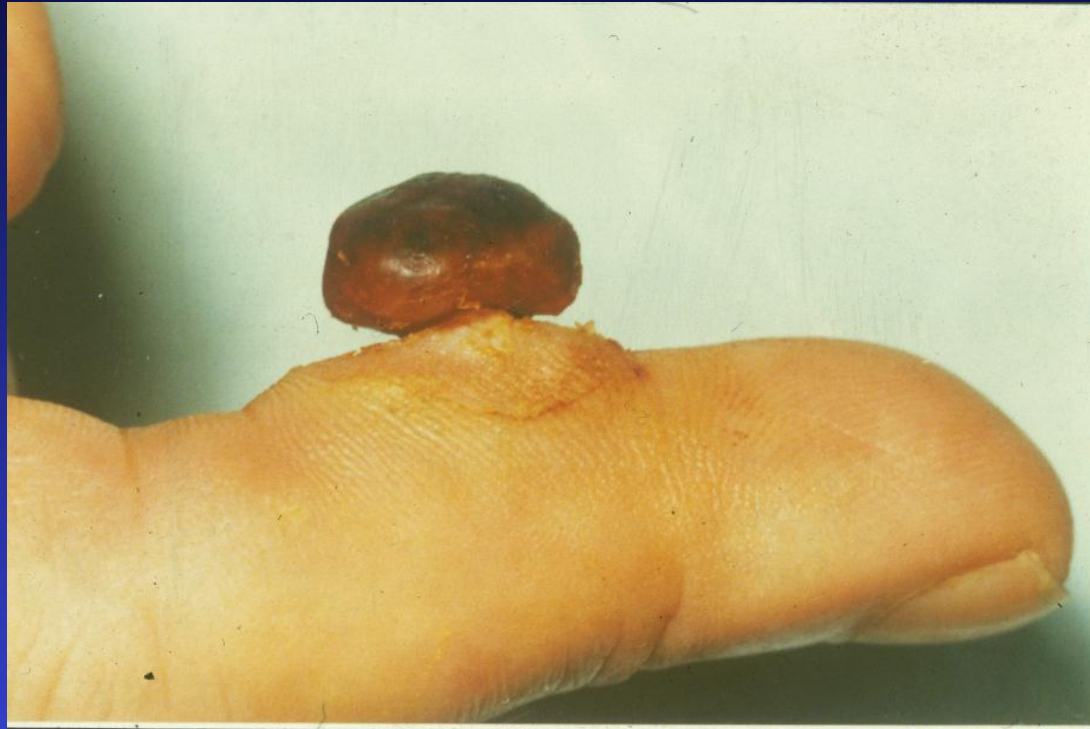

1. What is this skin rash ?
2. What is it associated with ?

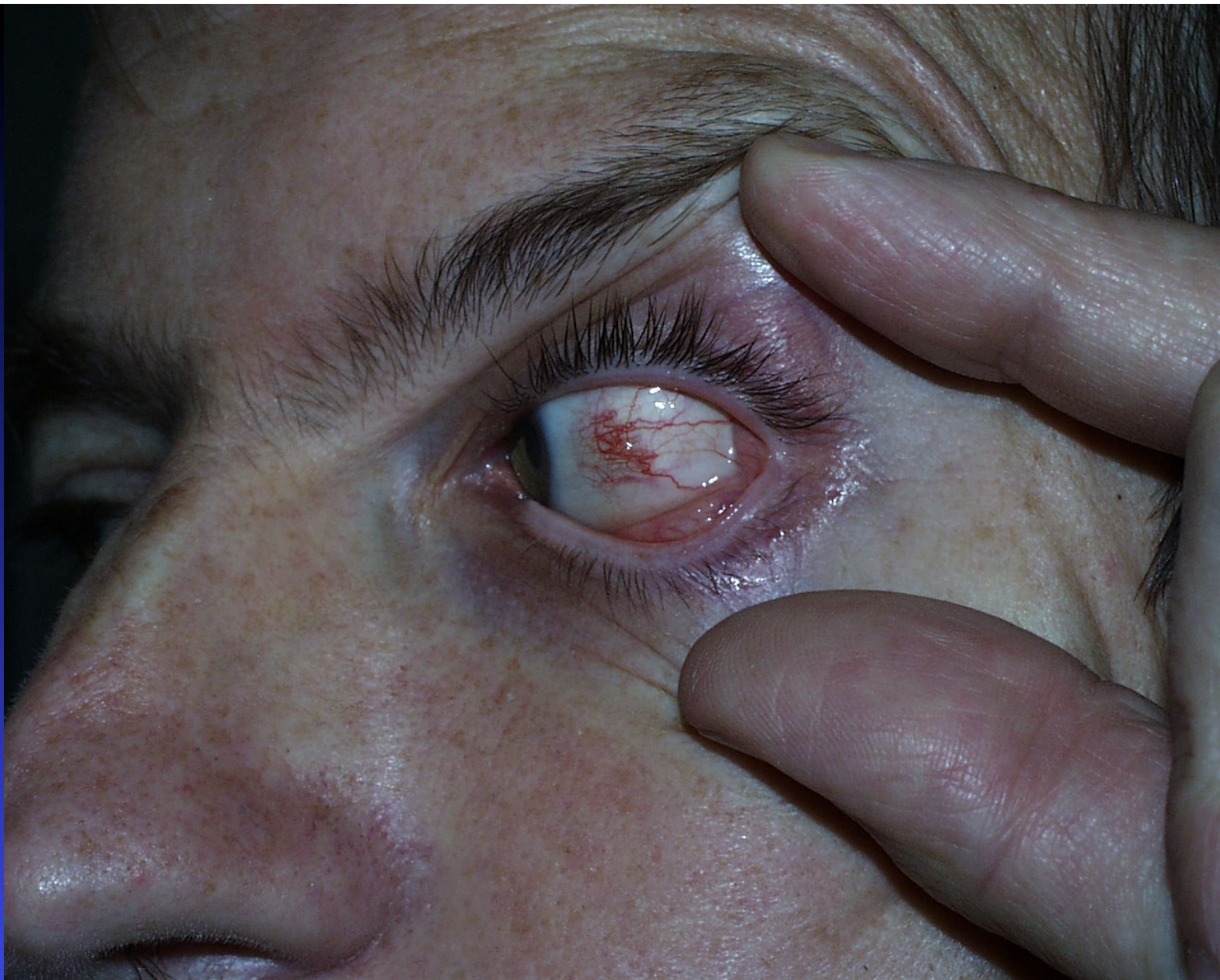

1. What is the diagnosis ?
2. What is the initial management of this patient ?



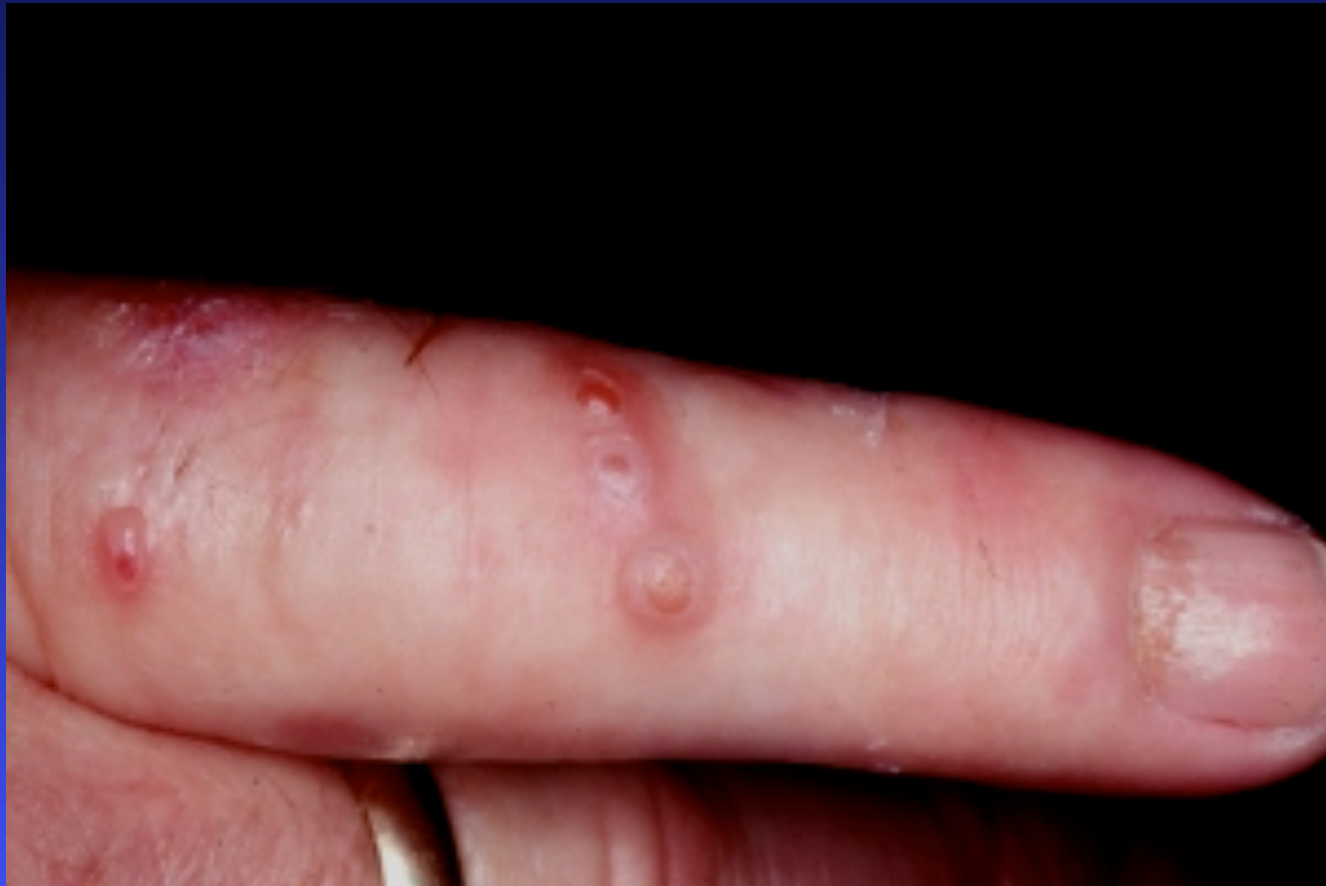

1. What is this lesion that appeared at the site of a minor wound ?
2. What treatment should be undertaken ?

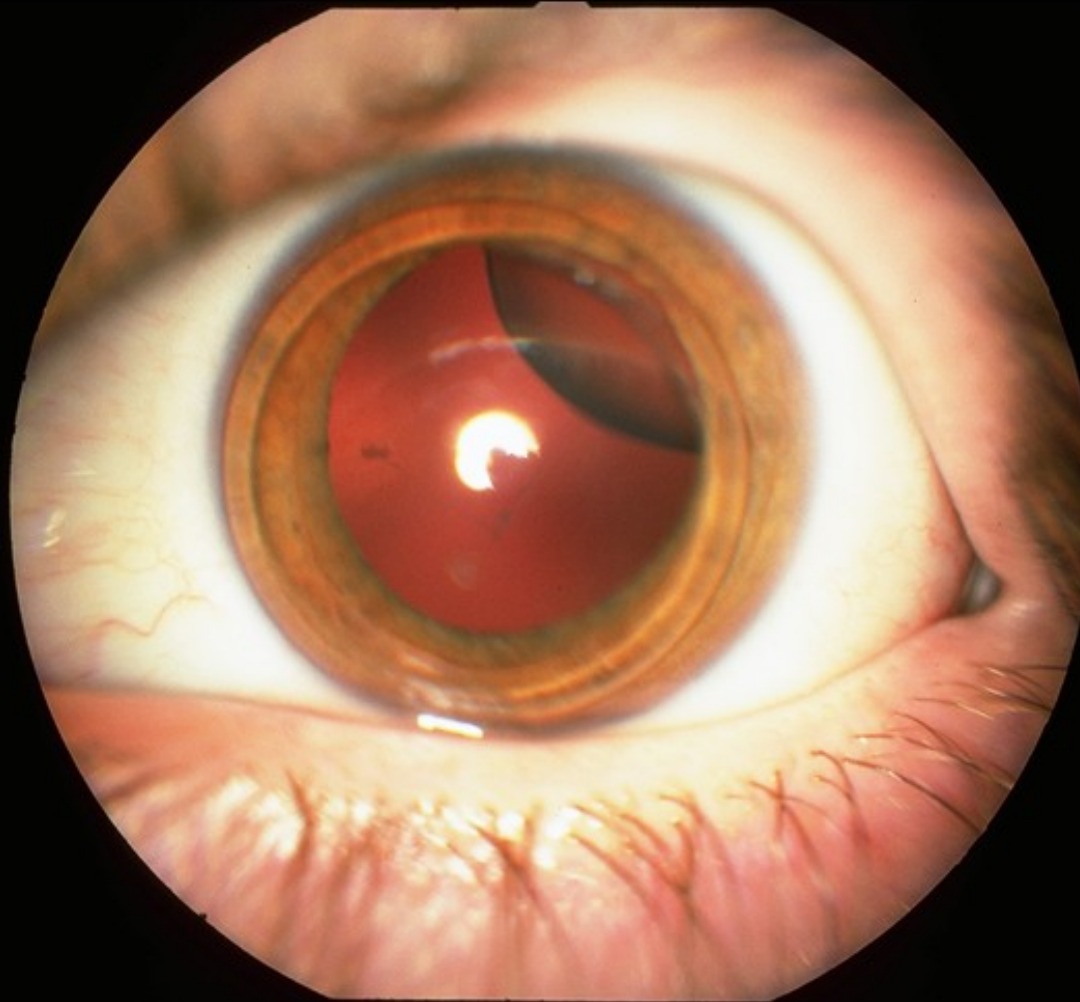


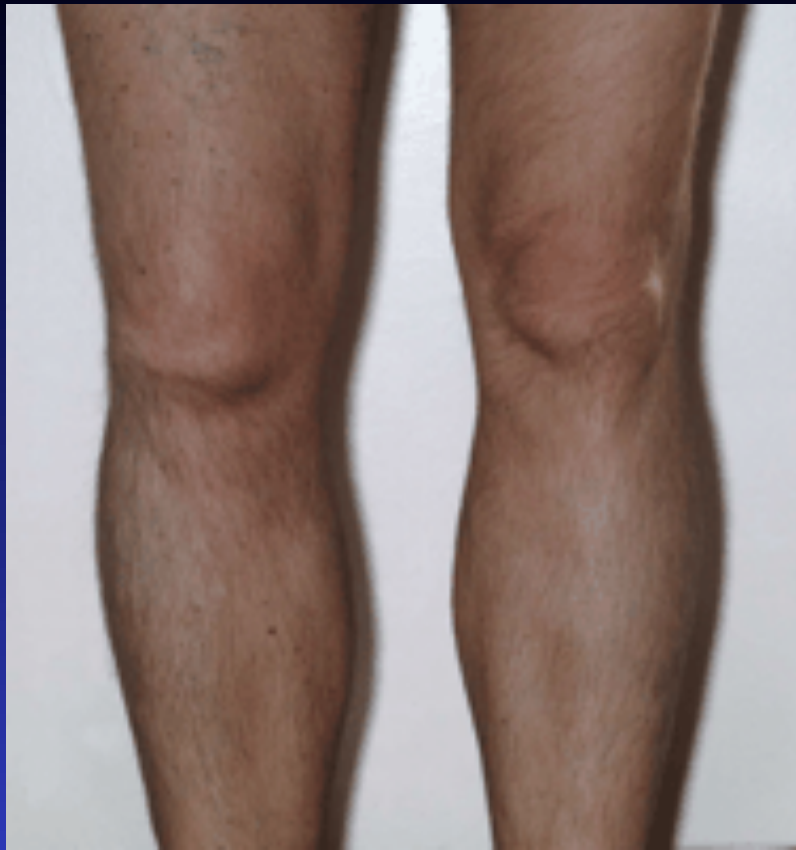1. Why does this patient complain of a sore eye ?
2. What is the management of this problem ?

1. A sheep farmer presents to A&E with these lesions on his finger - what is the diagnosis ?
2. What is the cause and how would you manage this patient ?

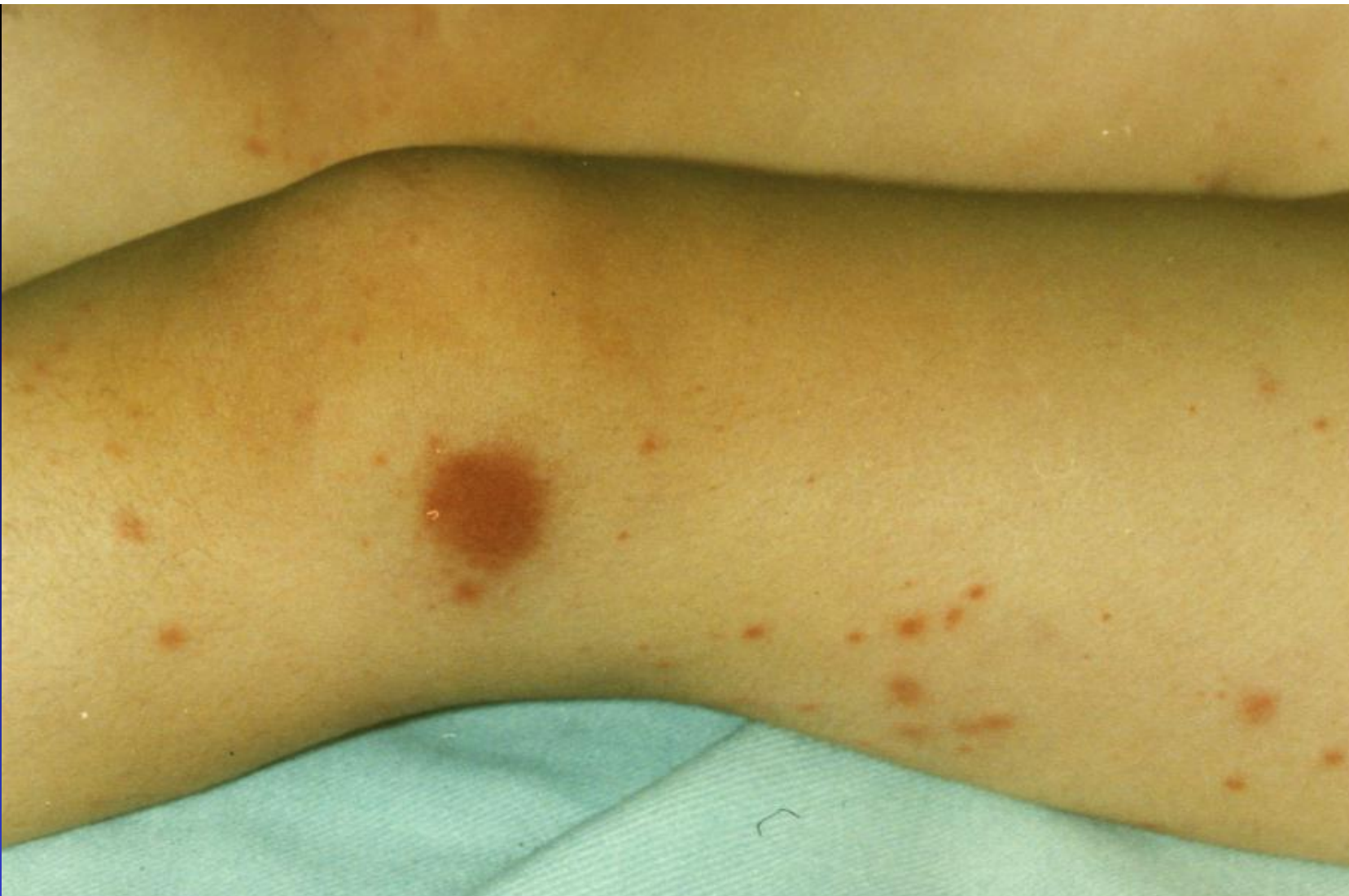

1. Why does this patient complain of a sudden loss of vision ?
2. What conditions can predispose a patient to this problem ?

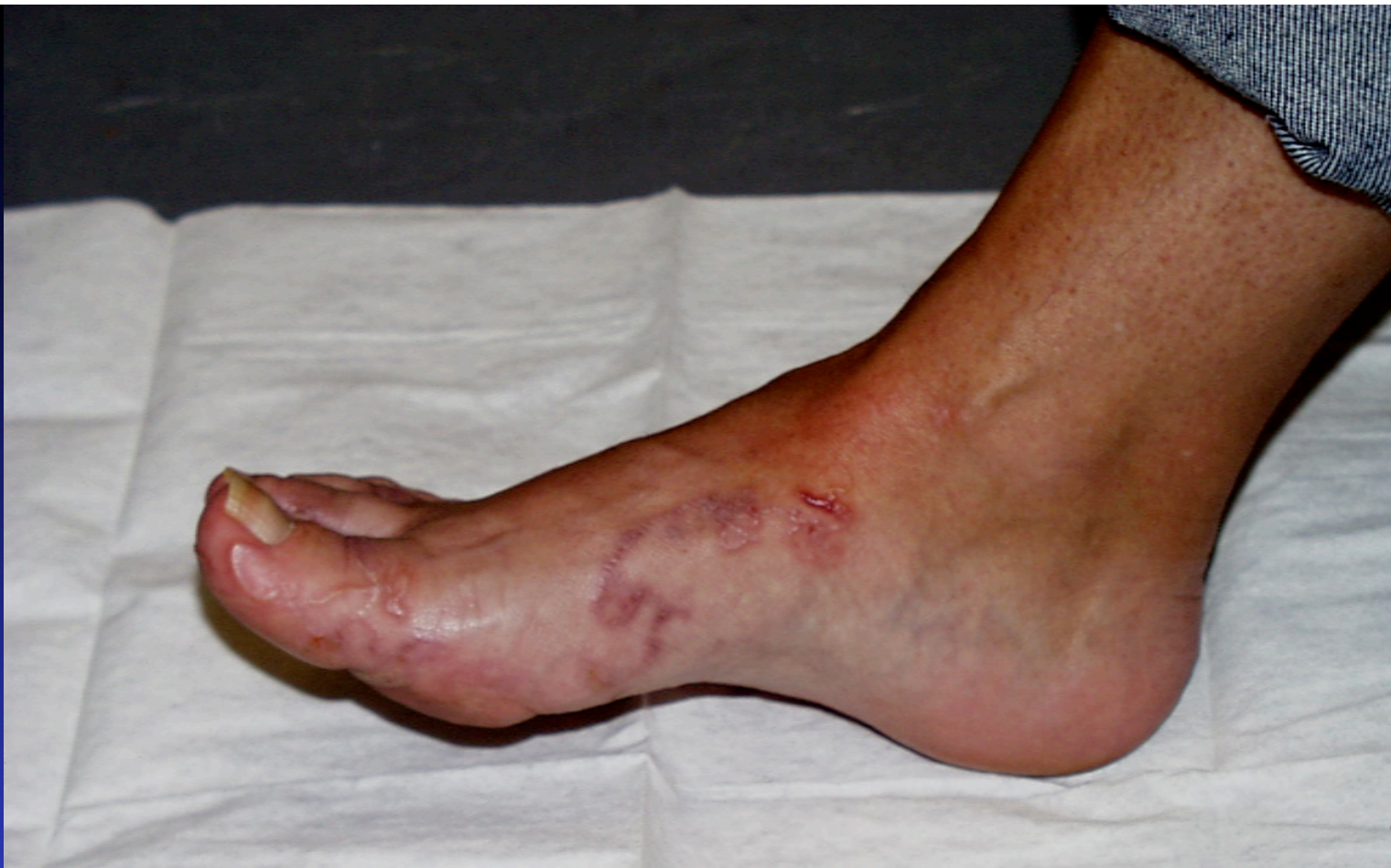



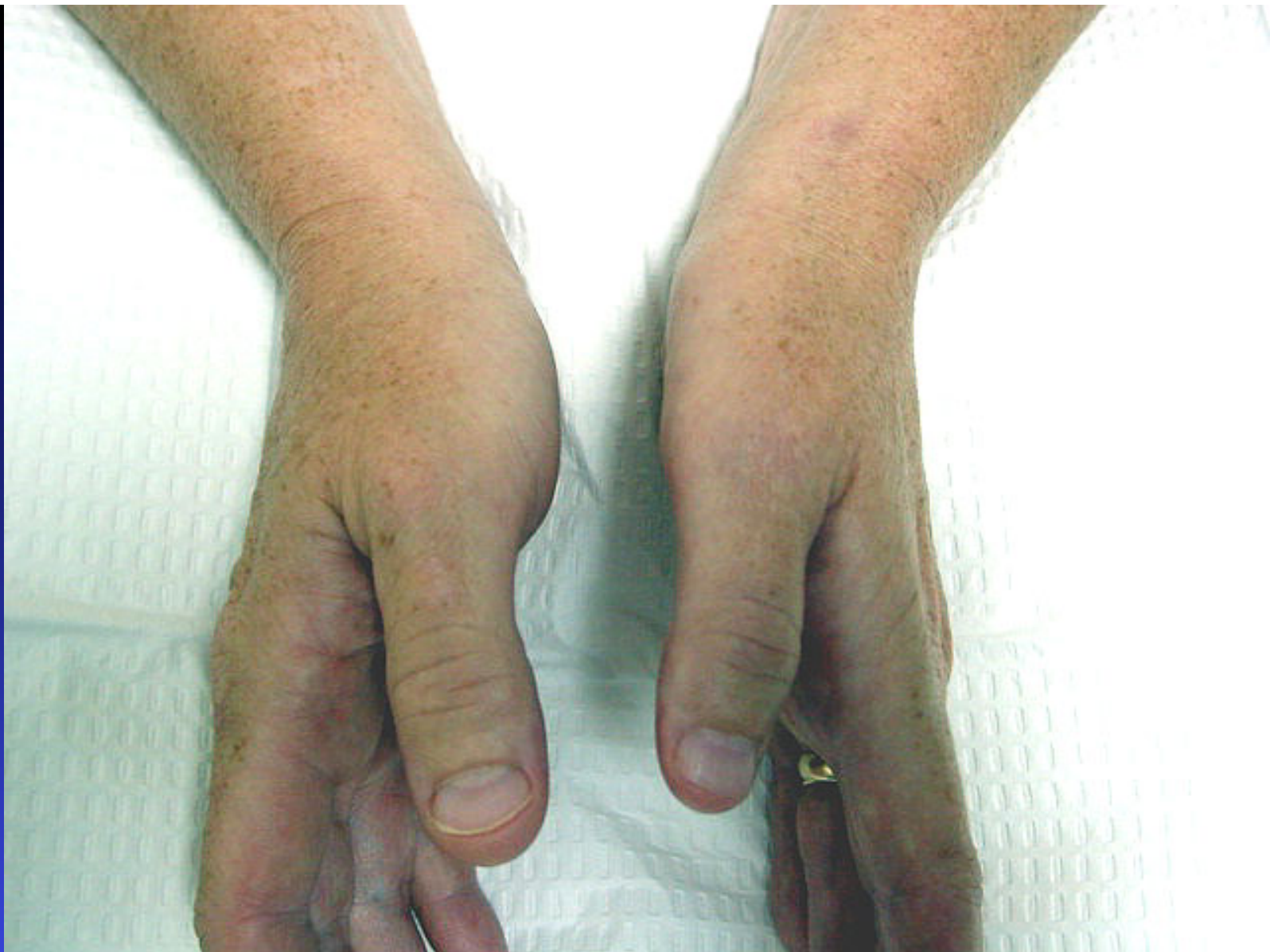1. This patient presents with a painful right knee following a fall– what specific questions would you ask the patient ?
2. What factors would govern whether an X-ray was necessary ?



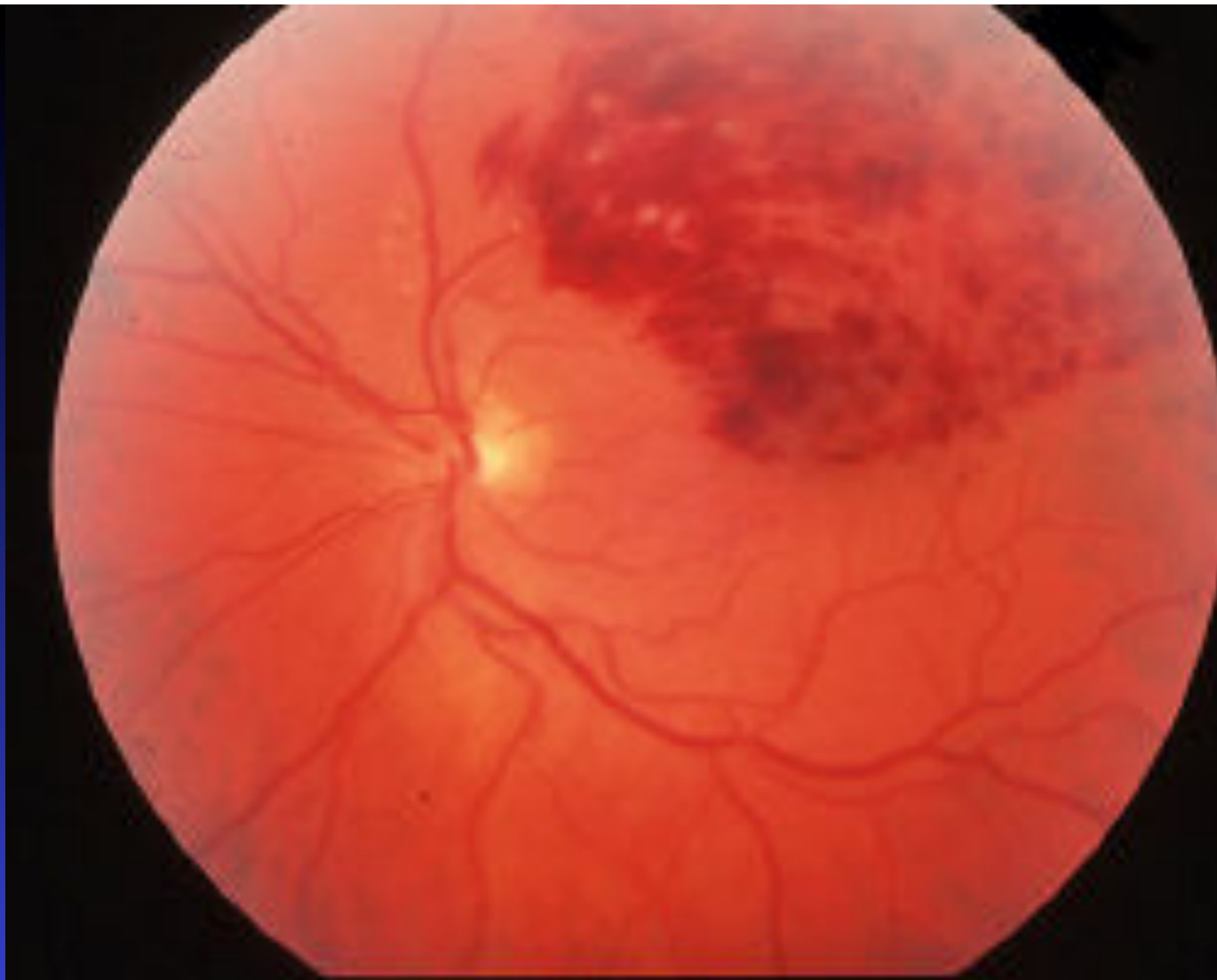1. What is the differential diagnosis of this rash in this 8 year old boy?
2. The patient complains of arthralgia and abdominal pain - what is the diagnosis?



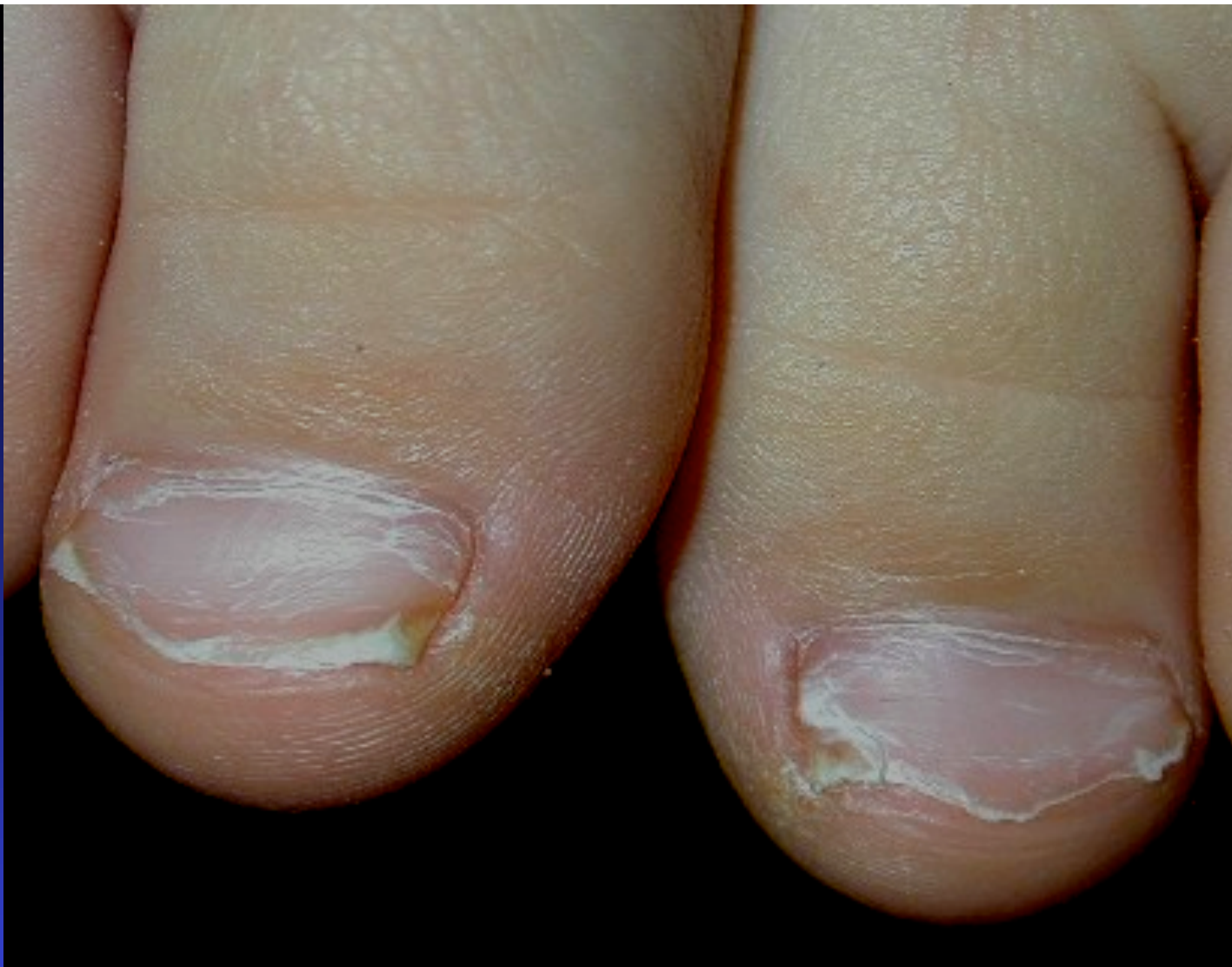1. This patient has returned from a holiday with this rash - what is the diagnosis ?
2. What are the causes and treatment of this condition ?



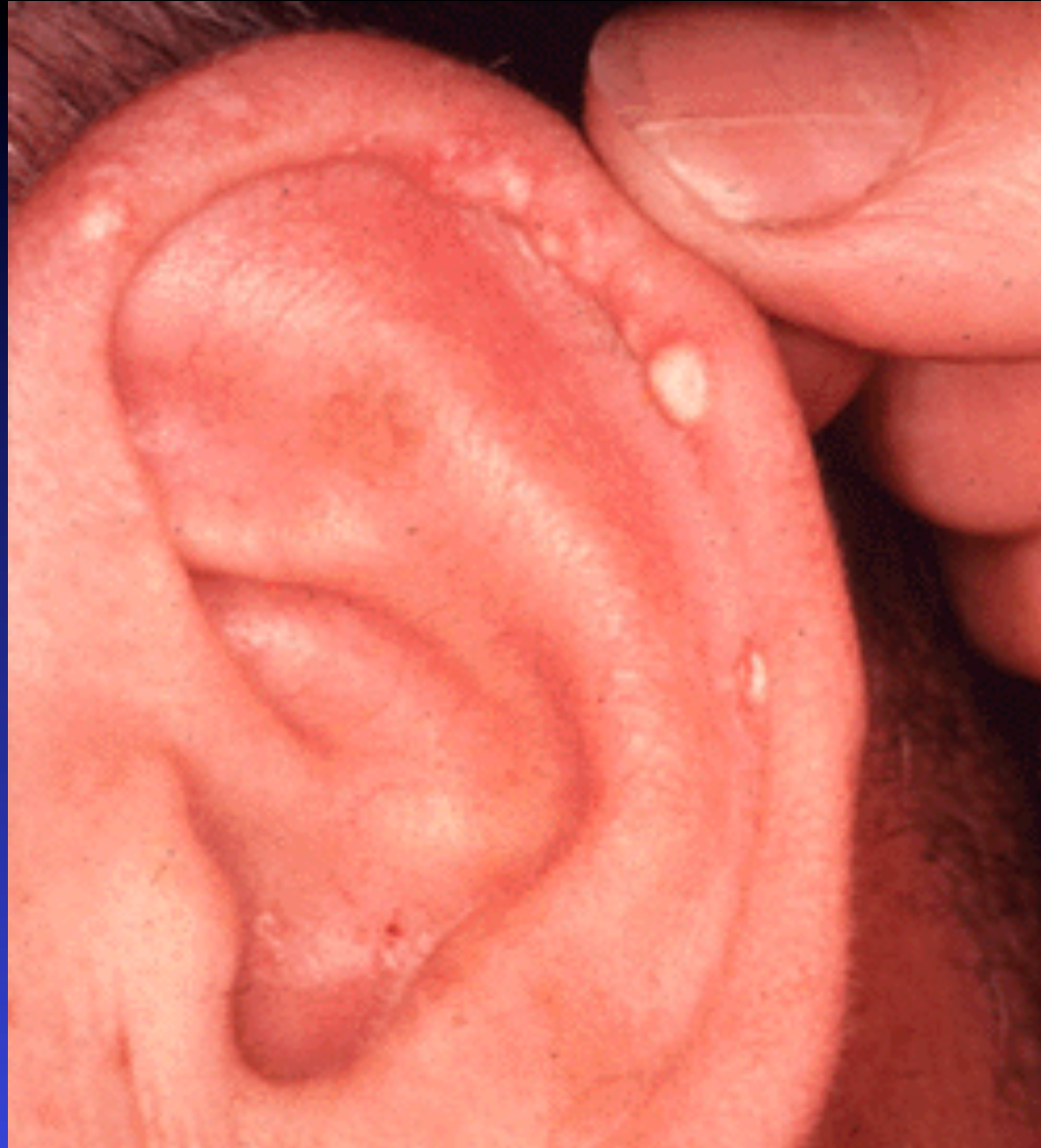1. What is the diagnosis ?
2. What abnormalities would you expect to find on examination ?



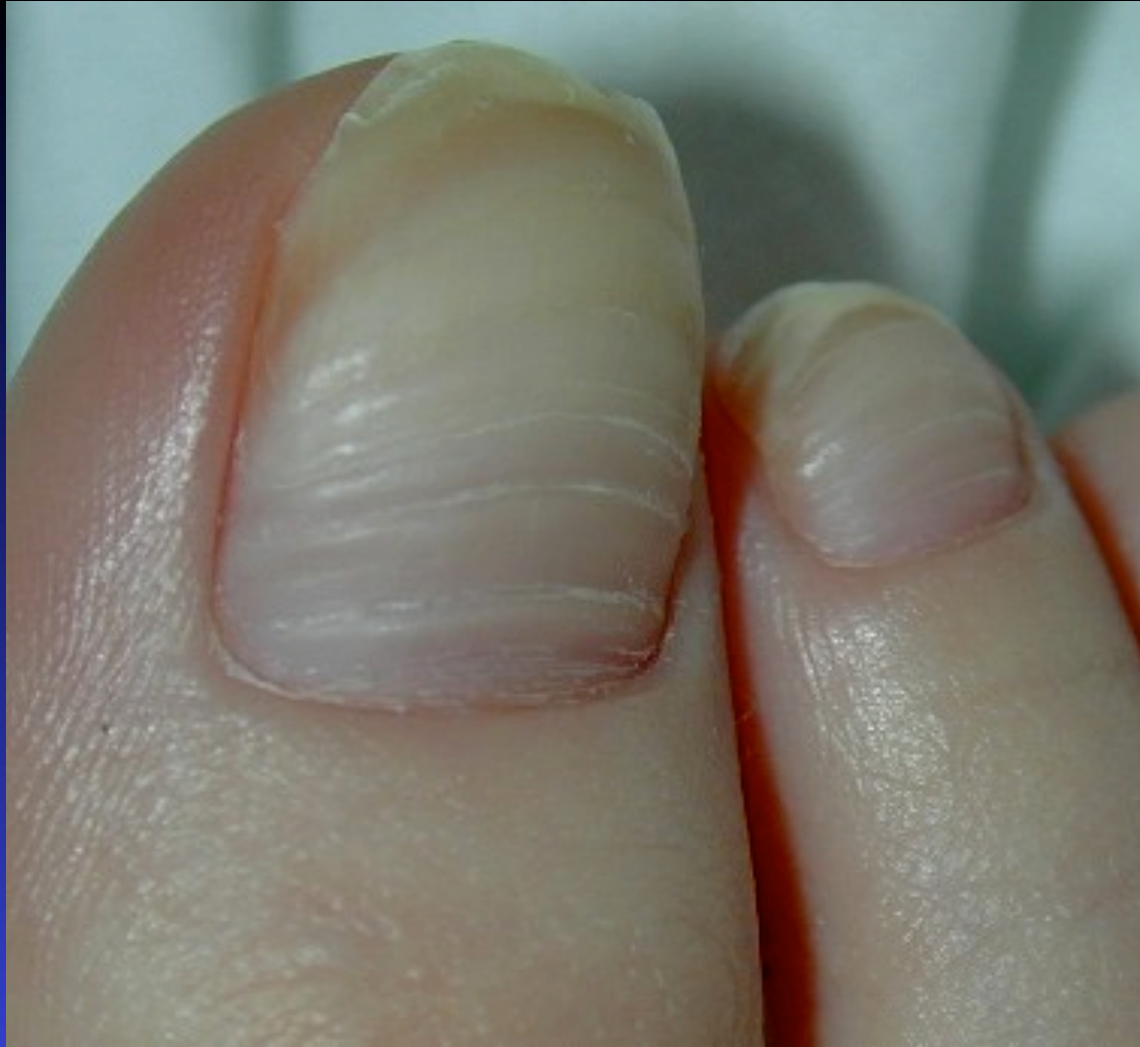1. This patient complains of partial sudden visual loss - what is the diagnosis ?
2. What systemic conditions are associated with this problem ?



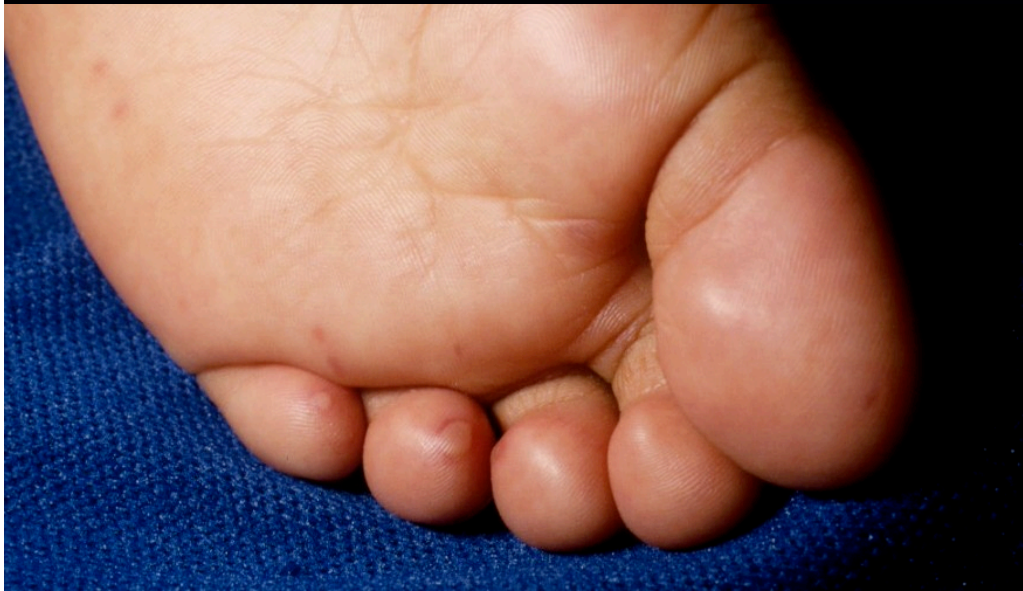1. What is this appearance of the nails known as and what is it caused by ?
2. What other abnormalities may be found on examination of this patient ?



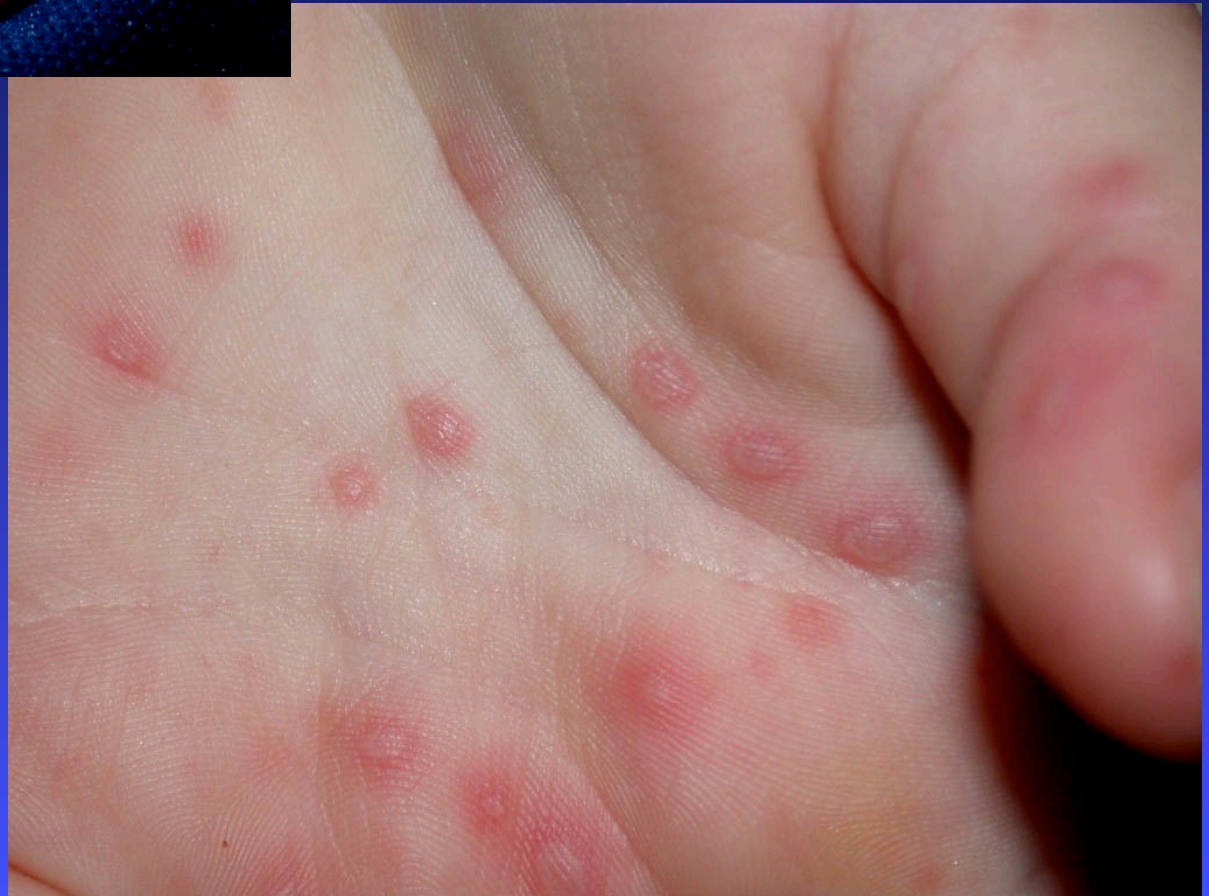1. What are these lesions on the ear ?
2. Where else might these lesions be found ?

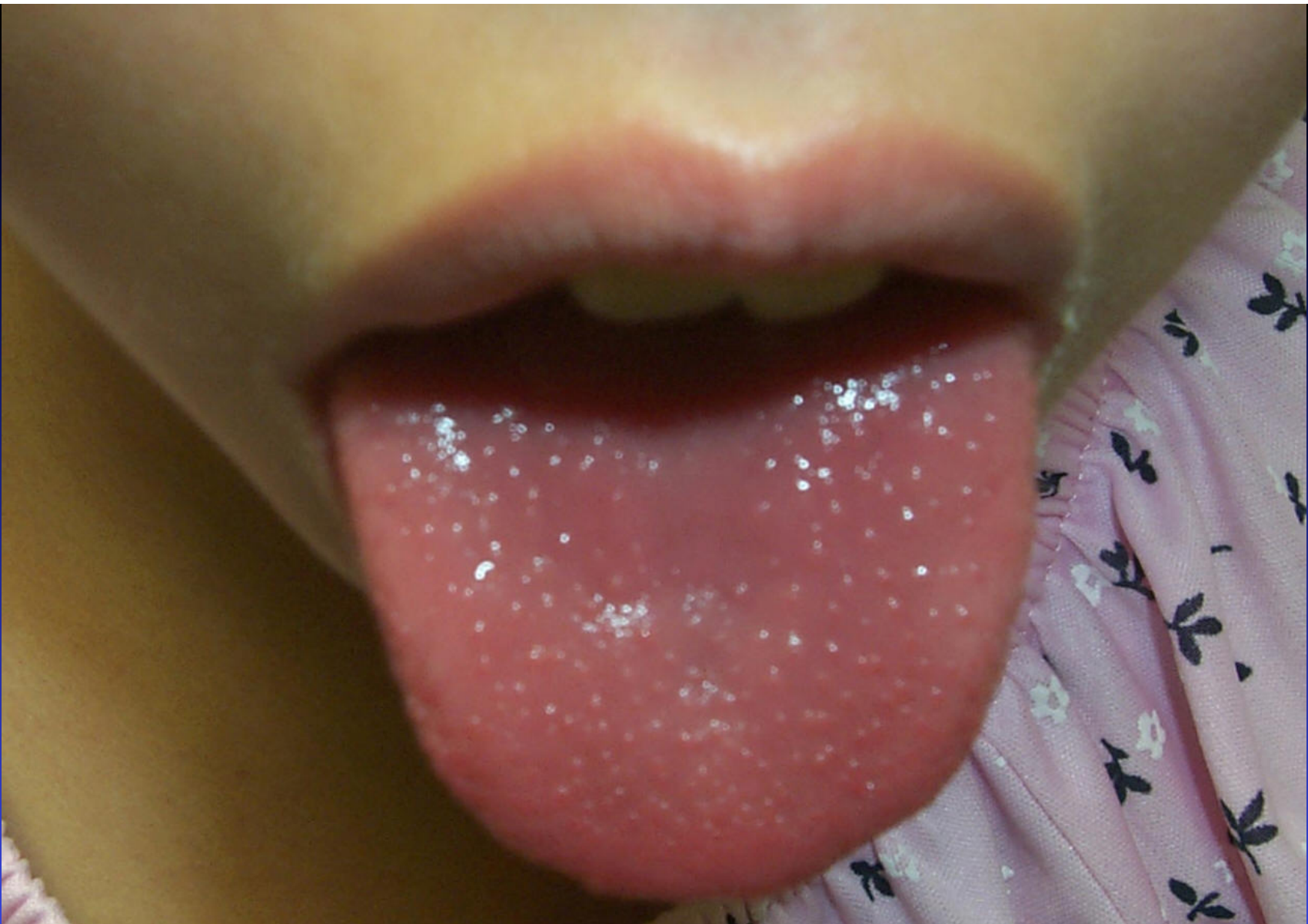

1. What is this abnormality known as ?
2. Why does it occur ?

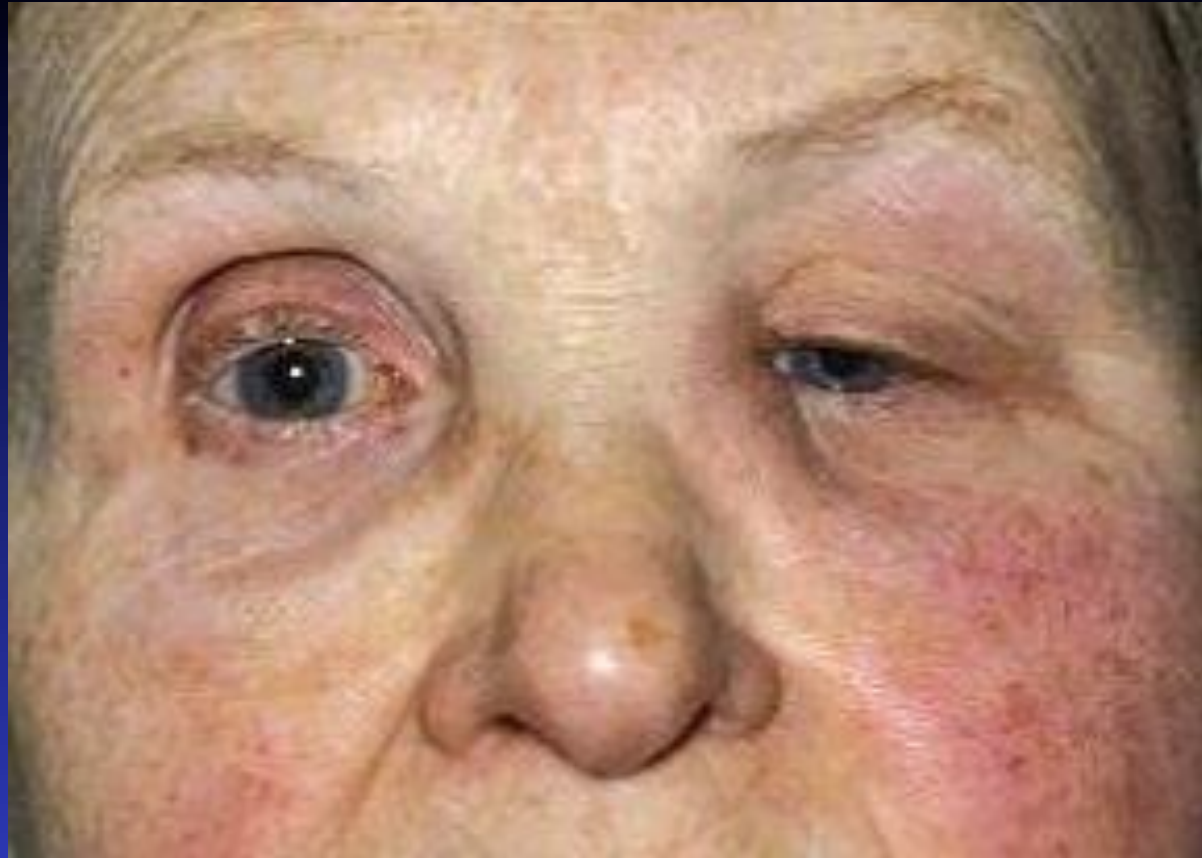

1. This rash has appeared on a child's hands and feet – where else would you look ?
2. What is the diagnosis and cause of this condition ?

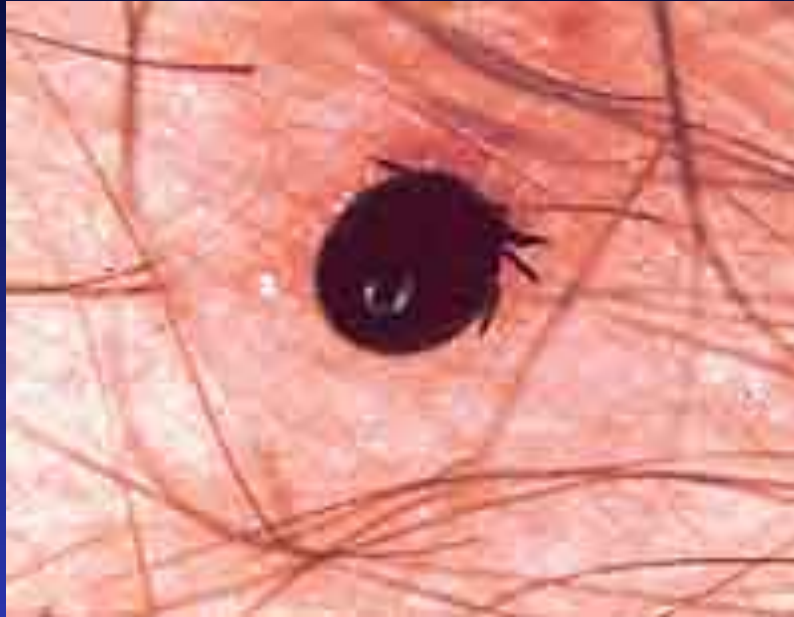




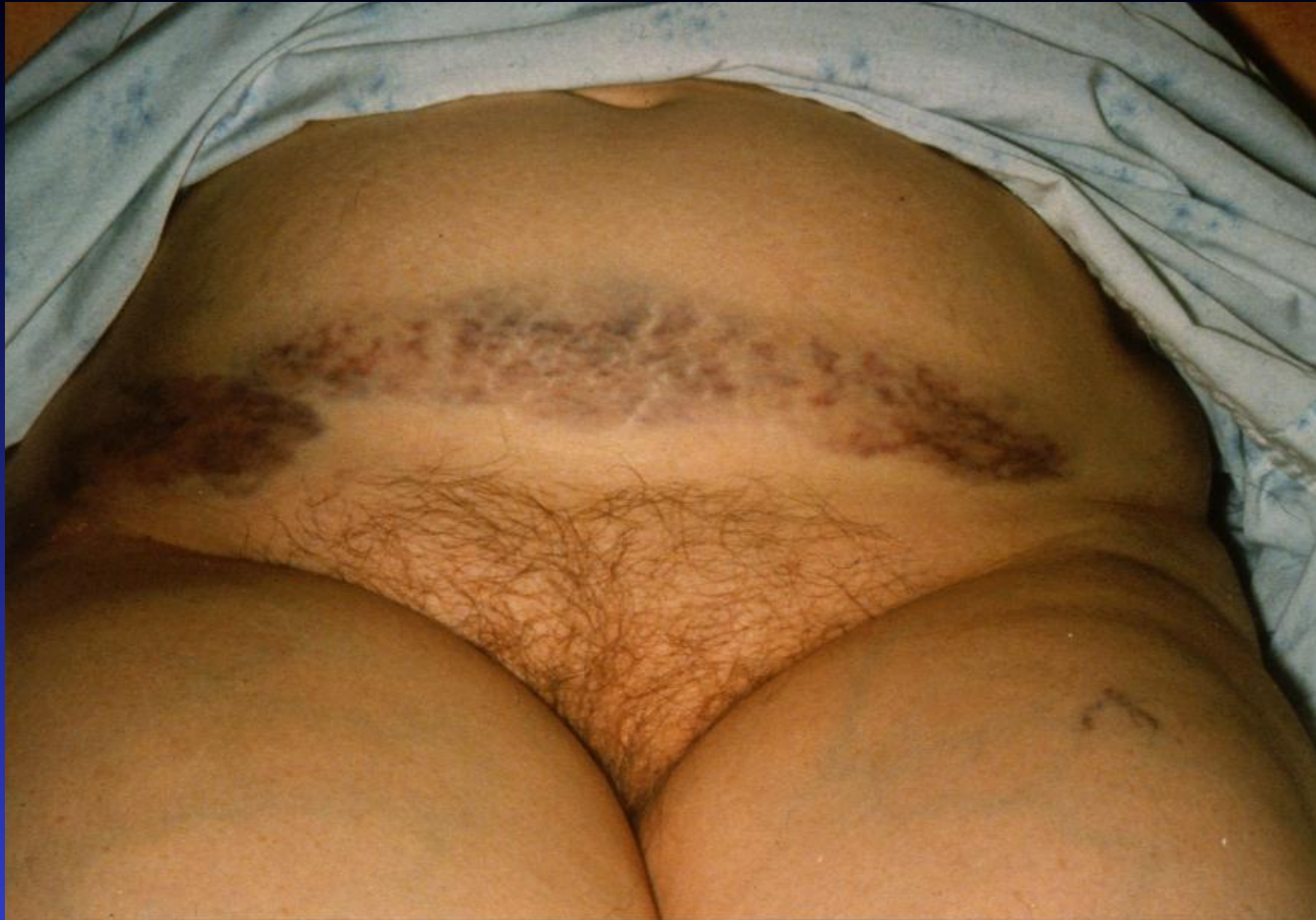1. This child has been unwell with a fever for 6 days - what is the diagnosis ?
2. What serious complications can occur in this condition ?



1. This patient complains of pain and swelling around their left eye - what is the diagnosis ?
2. What is the initial management of this patient ?



1. What is this ?
2. How would you remove it ?
3. What complications can arise from this ?



1. This patient has been involved in a RTA – what is the cause of this appearance on the abdomen ?
2. What are the possible complications of this injury ?
3. What investigations are necessary in this patient who complains of abdominal pain ?

Any Questions ?