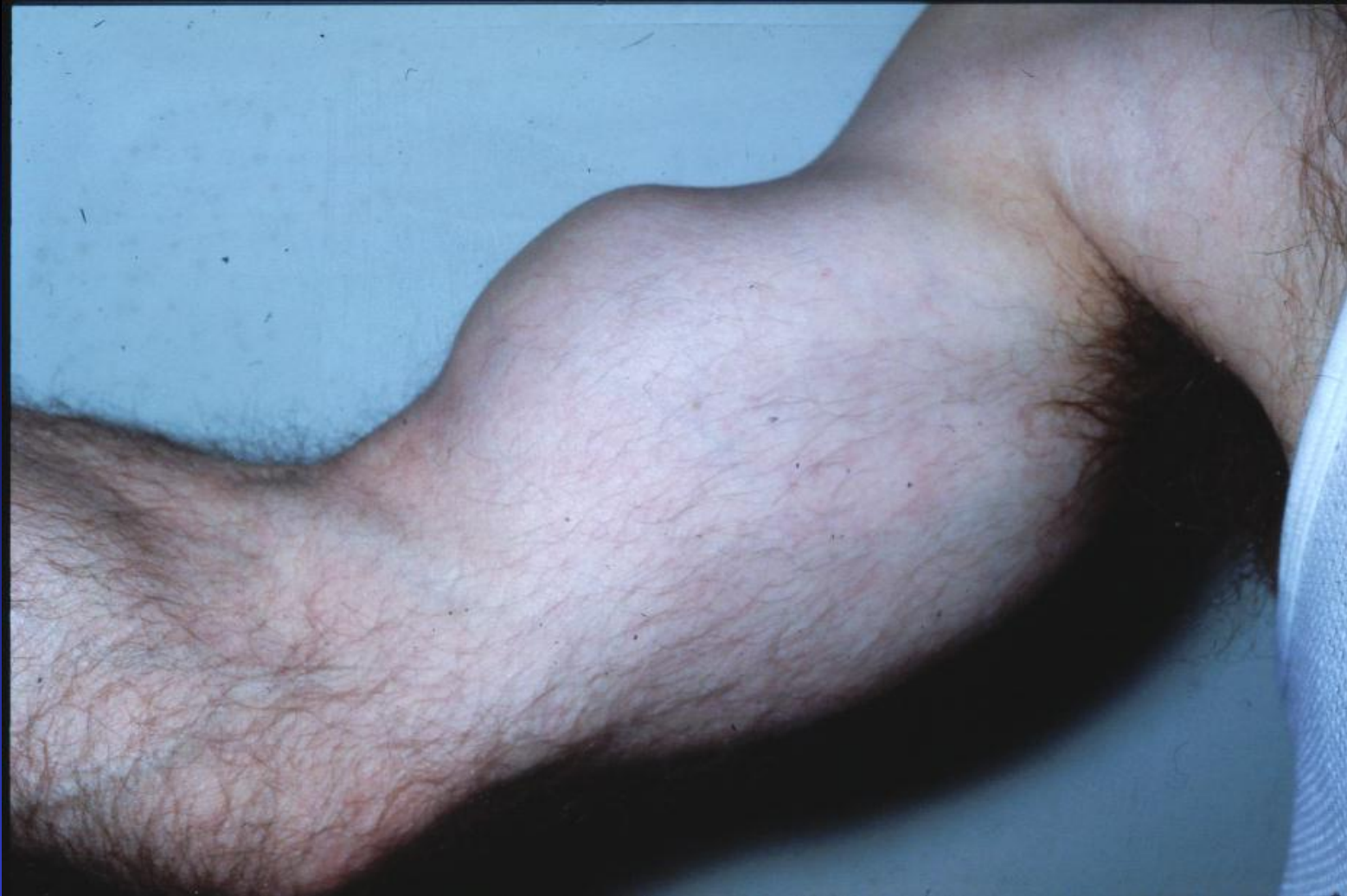

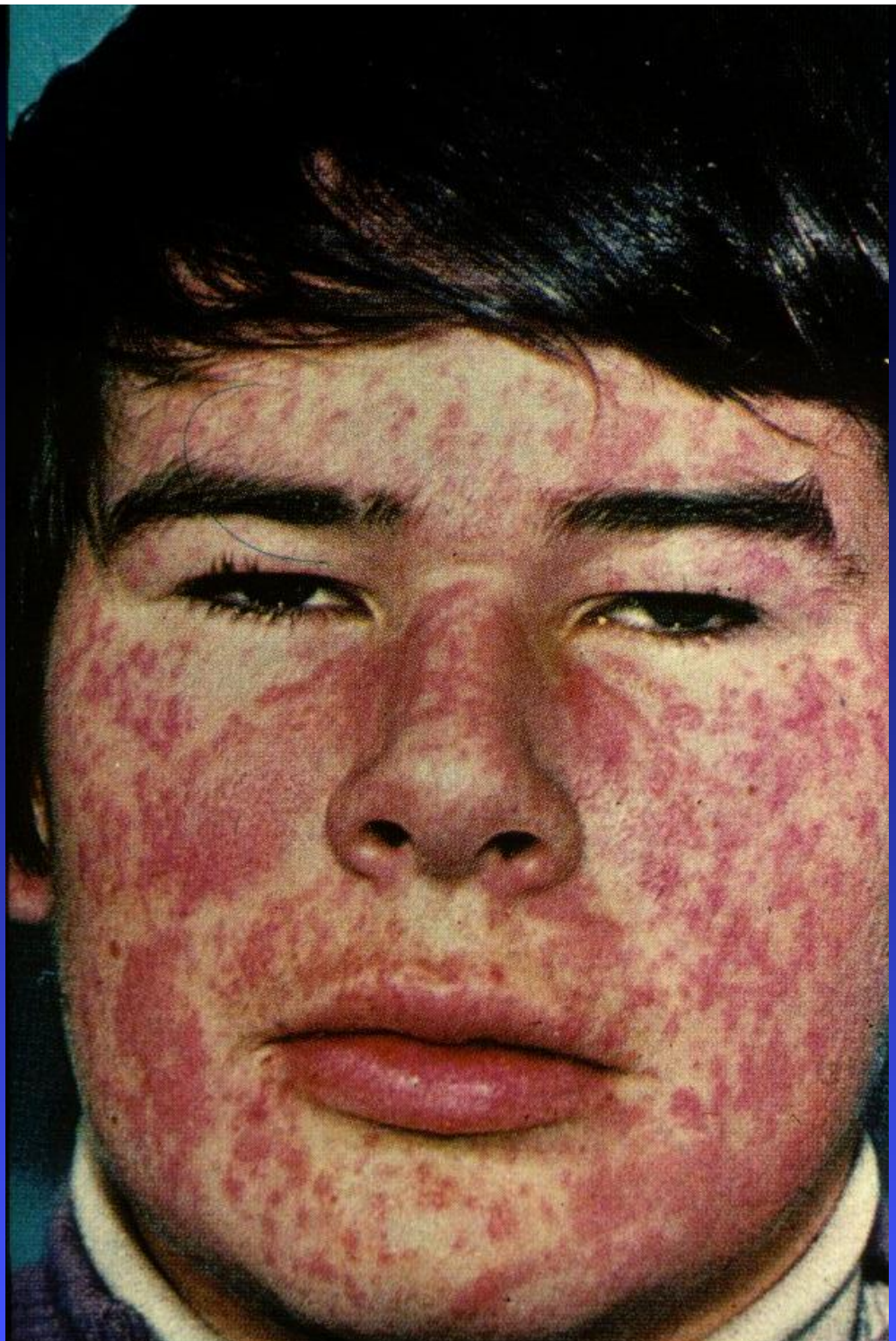

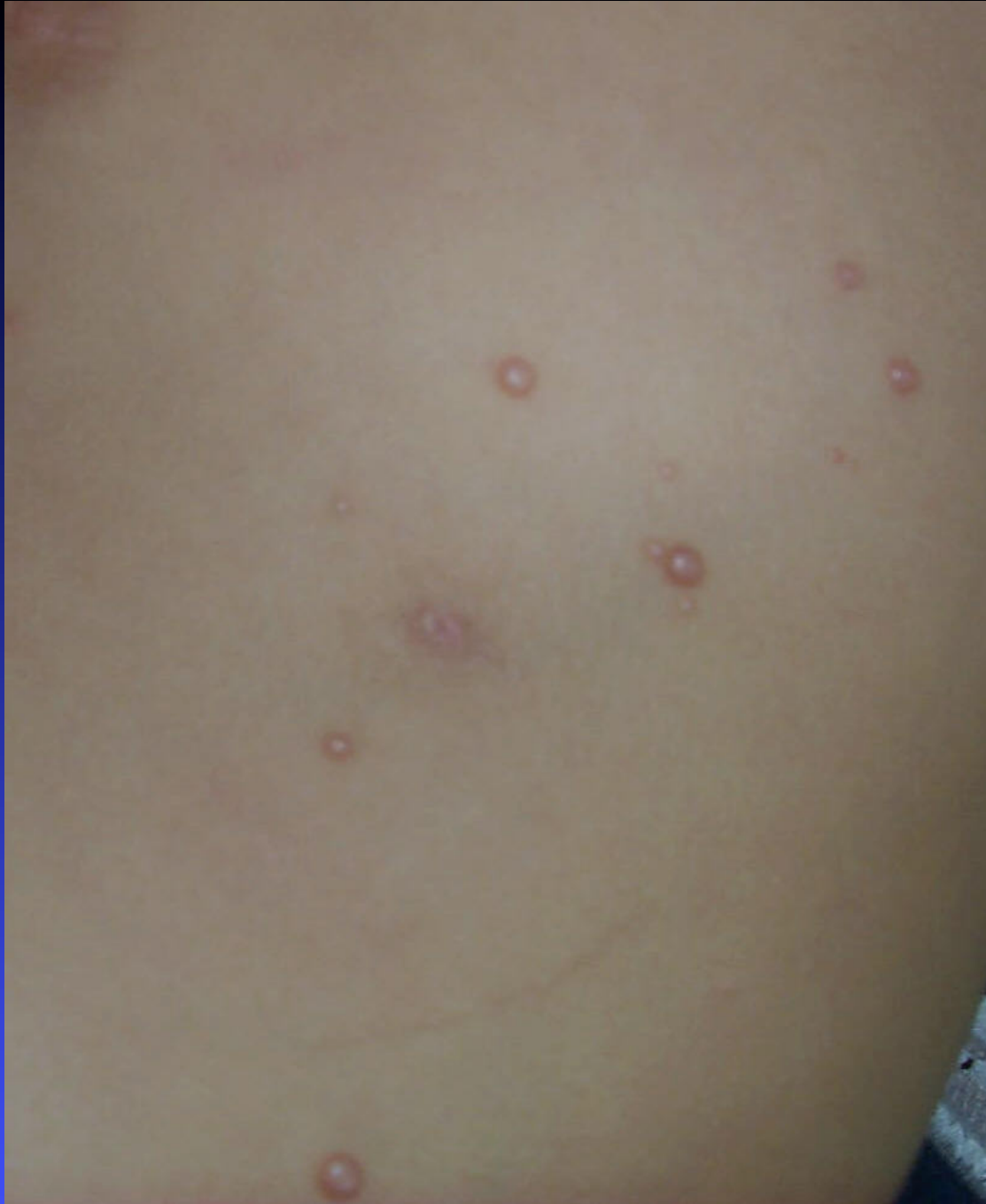
Picture Quiz 2



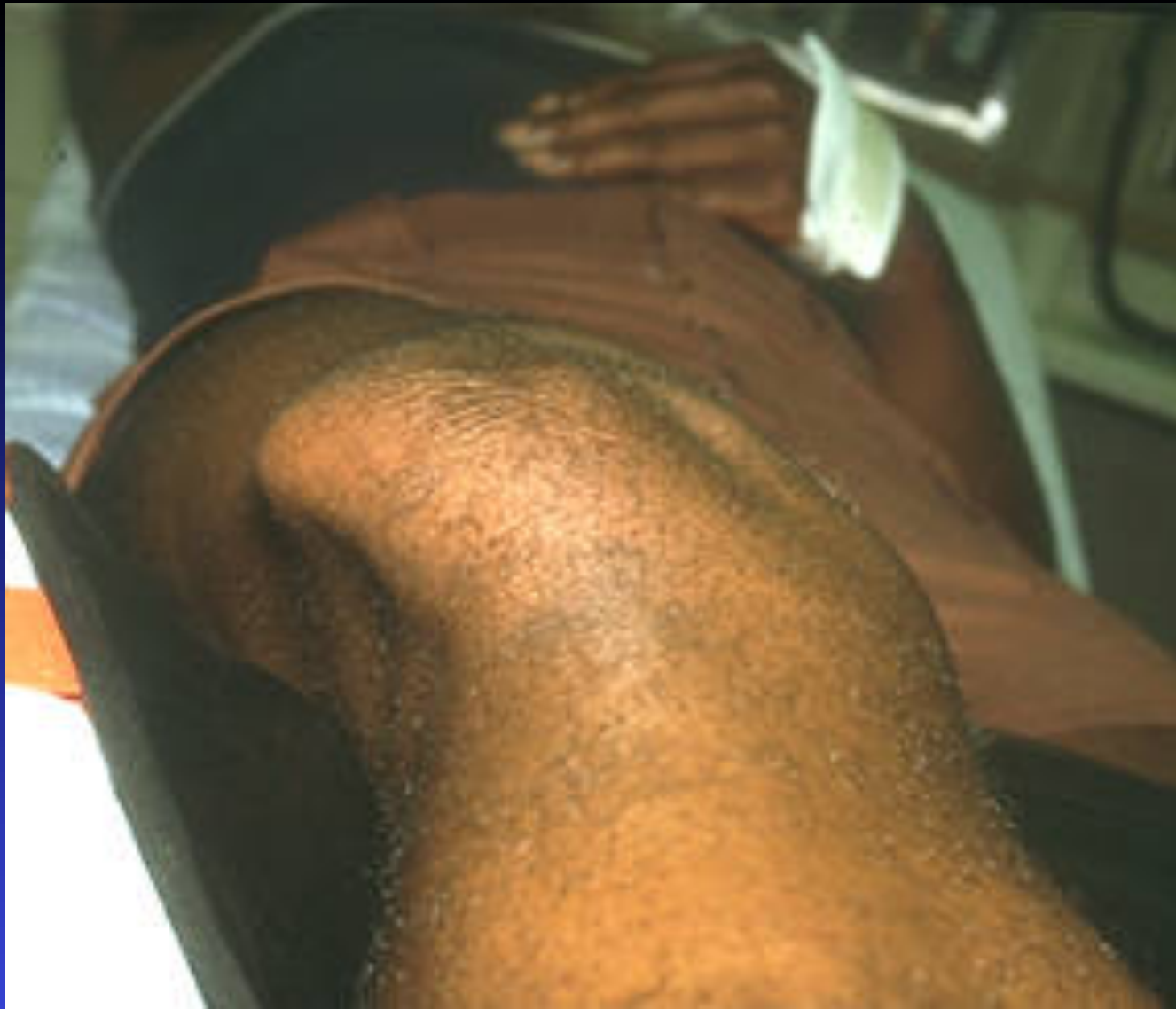1. This patient presents with sudden pain in the upper arm after exercise – what injury has been sustained ?

1. How would you describe this rash ?
2. What is the diagnosis ?

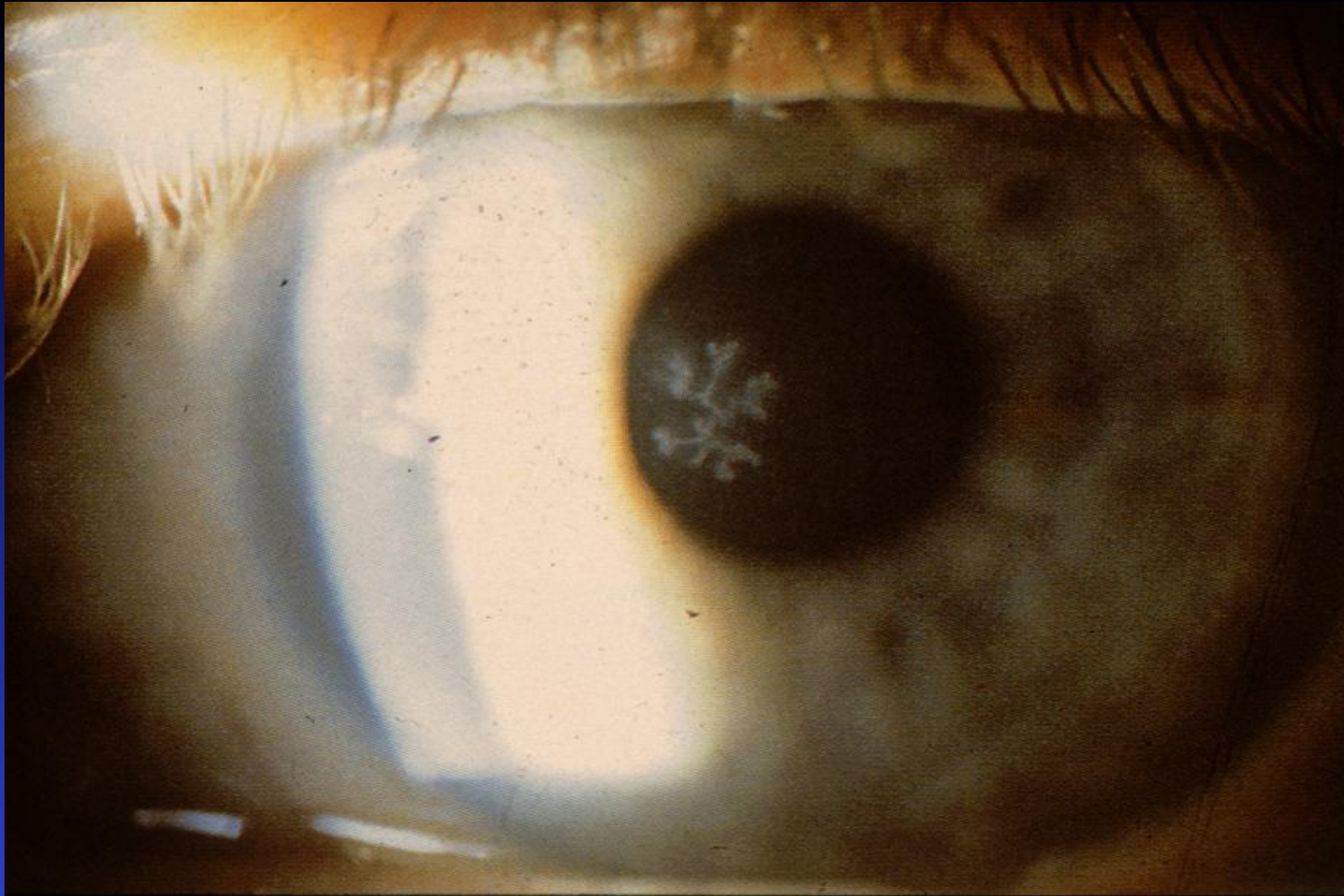




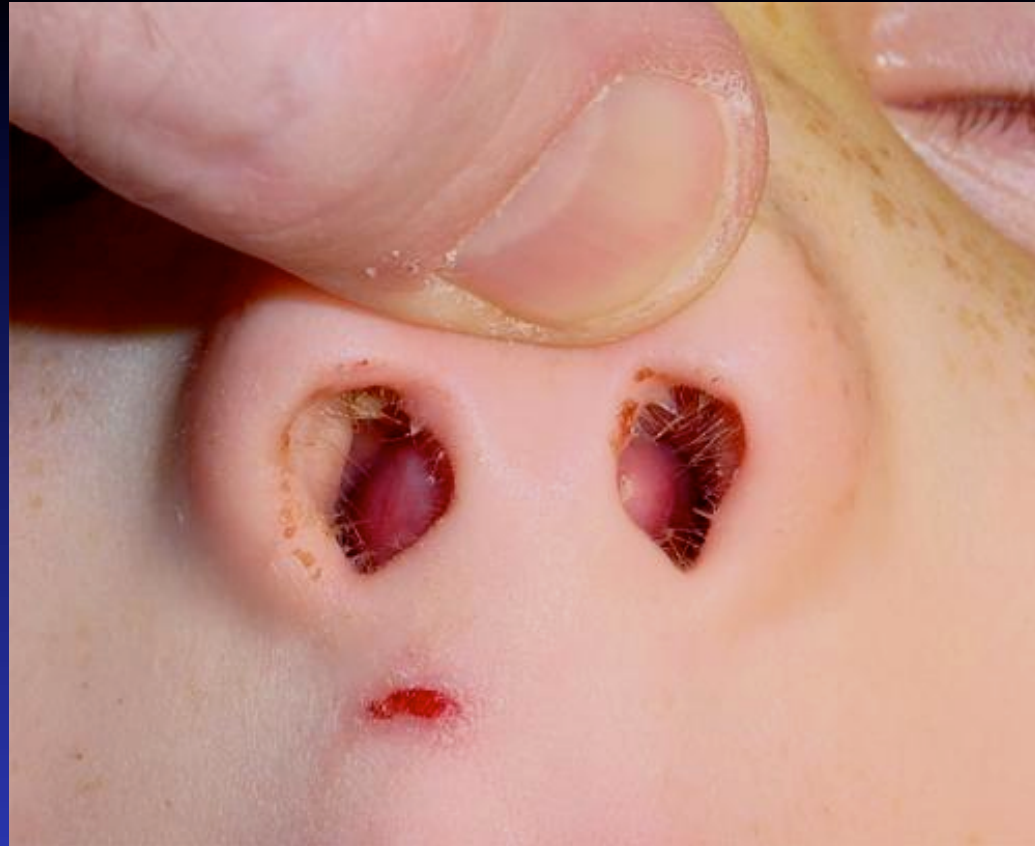
1. What is this rash ?
2. This patient is HIV positive – list other skin problems seen in this condition ?



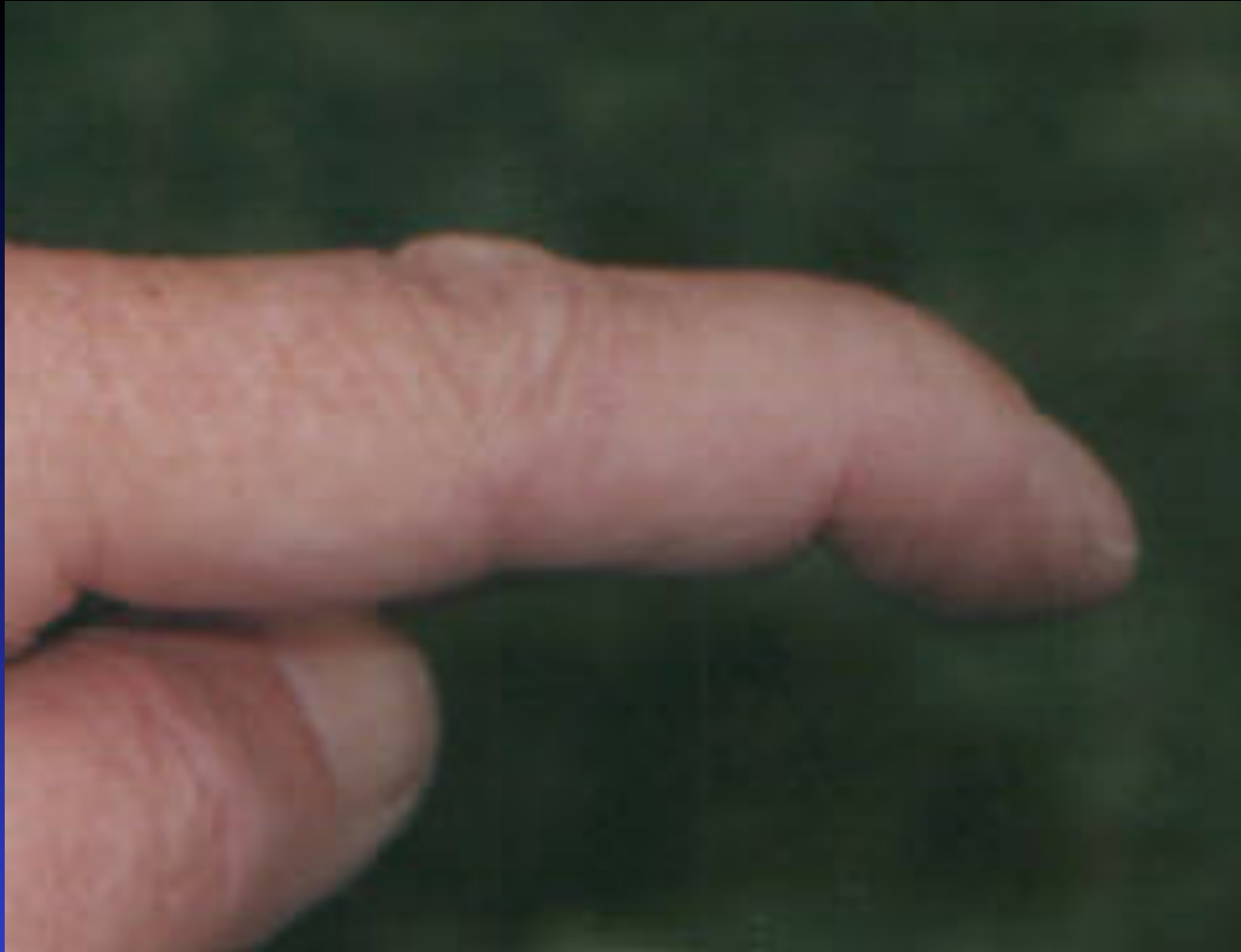1. What is this problem and what treatment is necessary ?



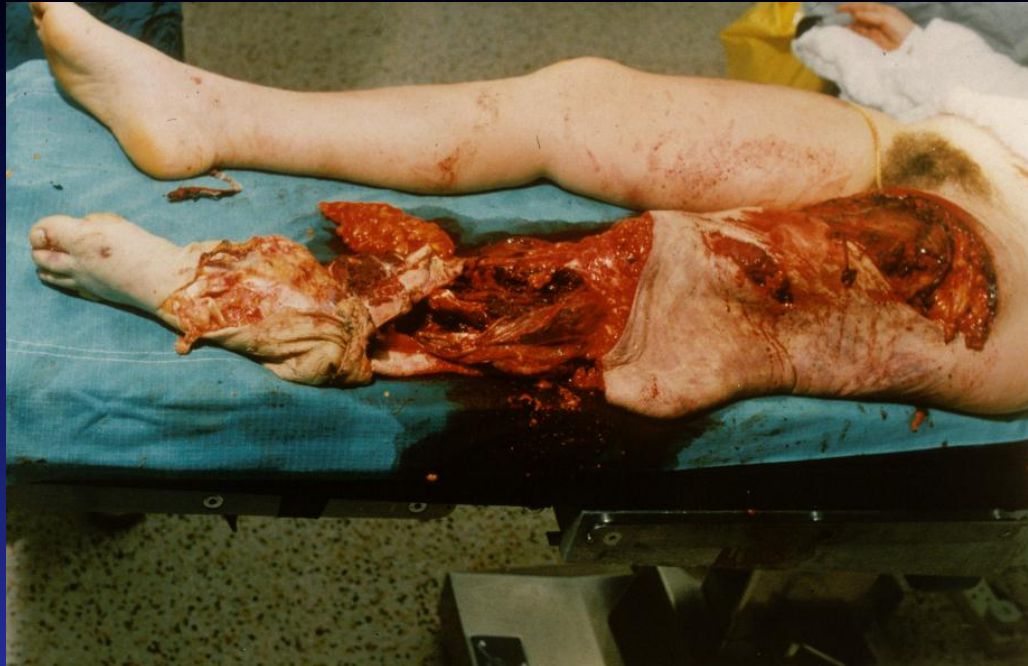
1. What is the cause of this problem and what symptoms would the patient complain of ?



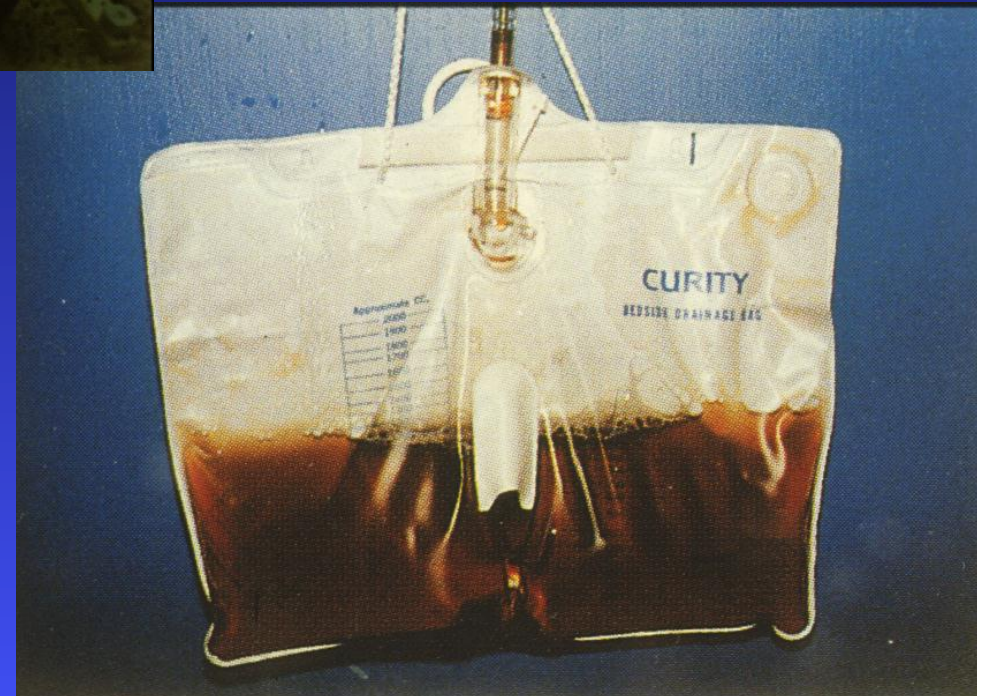
1. This patient has sustained an injury to their nose - what problem is shown and what treatment is necessary ?
2. What complication may occur if this is not treated ?



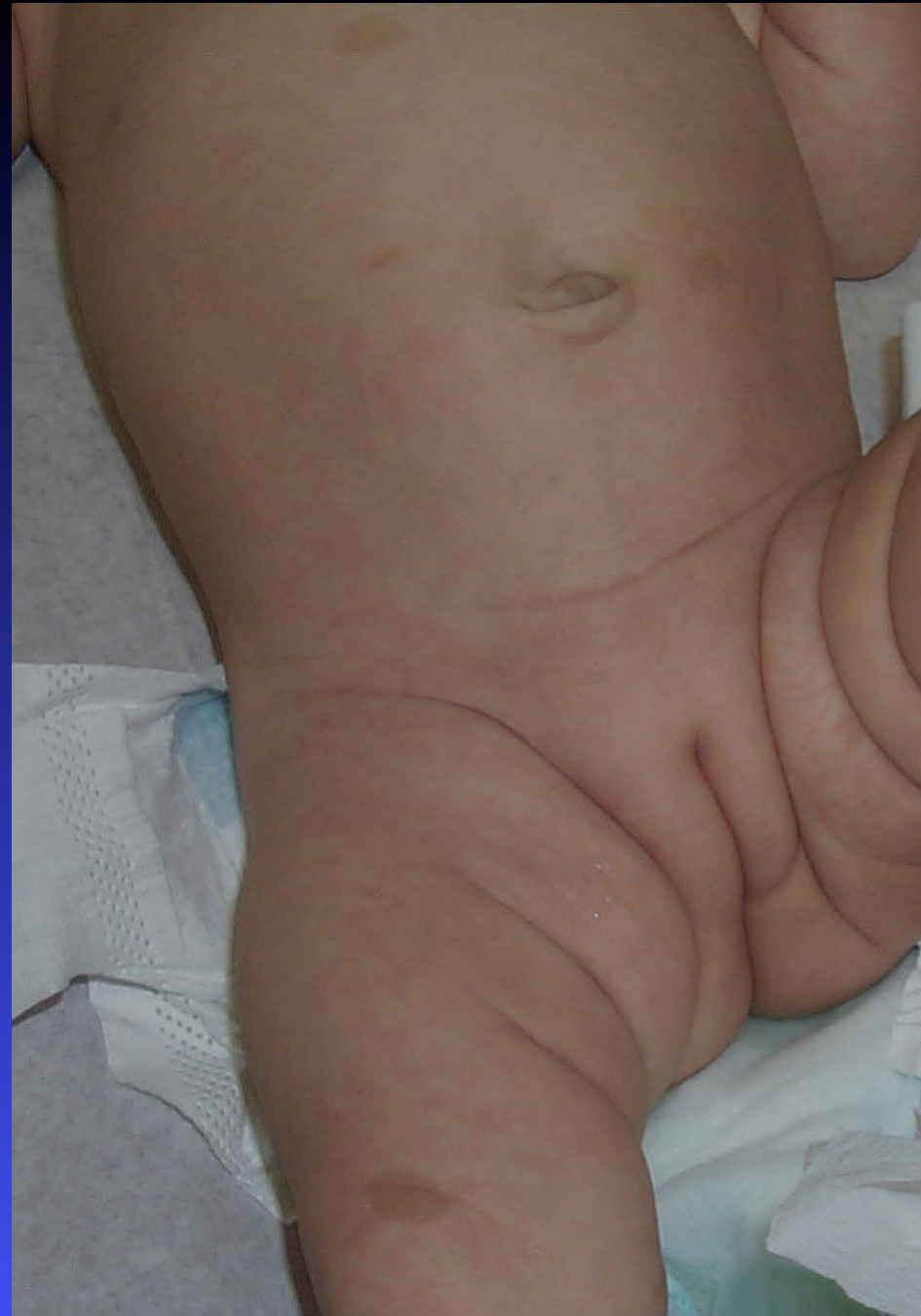1. Describe anatomically the injury that has occurred
2. What factors would help to decide whether operative management was needed for this injury ?

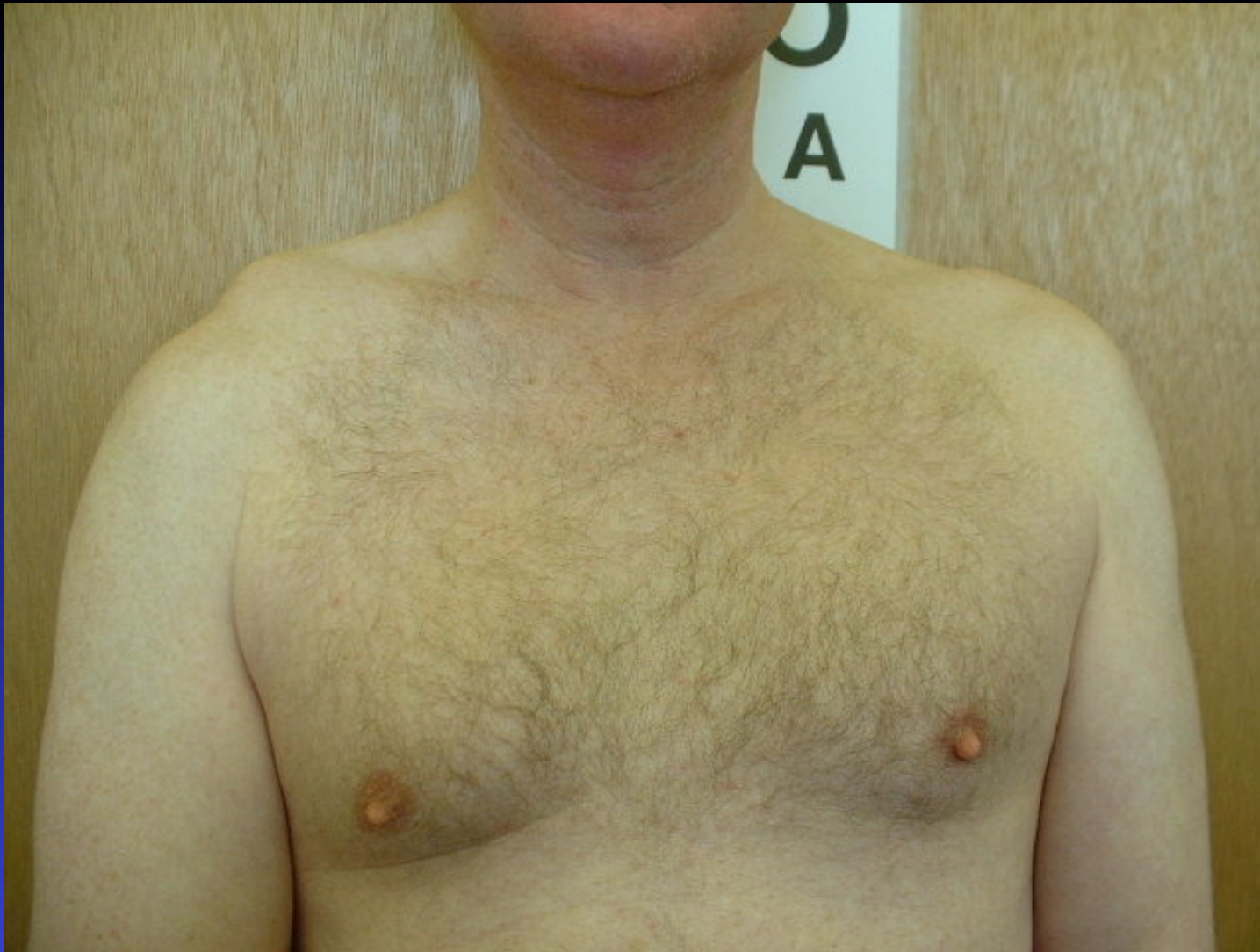

1. Following catheterisation this patient's urine has this appearance – explain why ?
2. What complications may arise as a result of this problem and what treatment is necessary ?
3. List 3 other causes of this problem ?

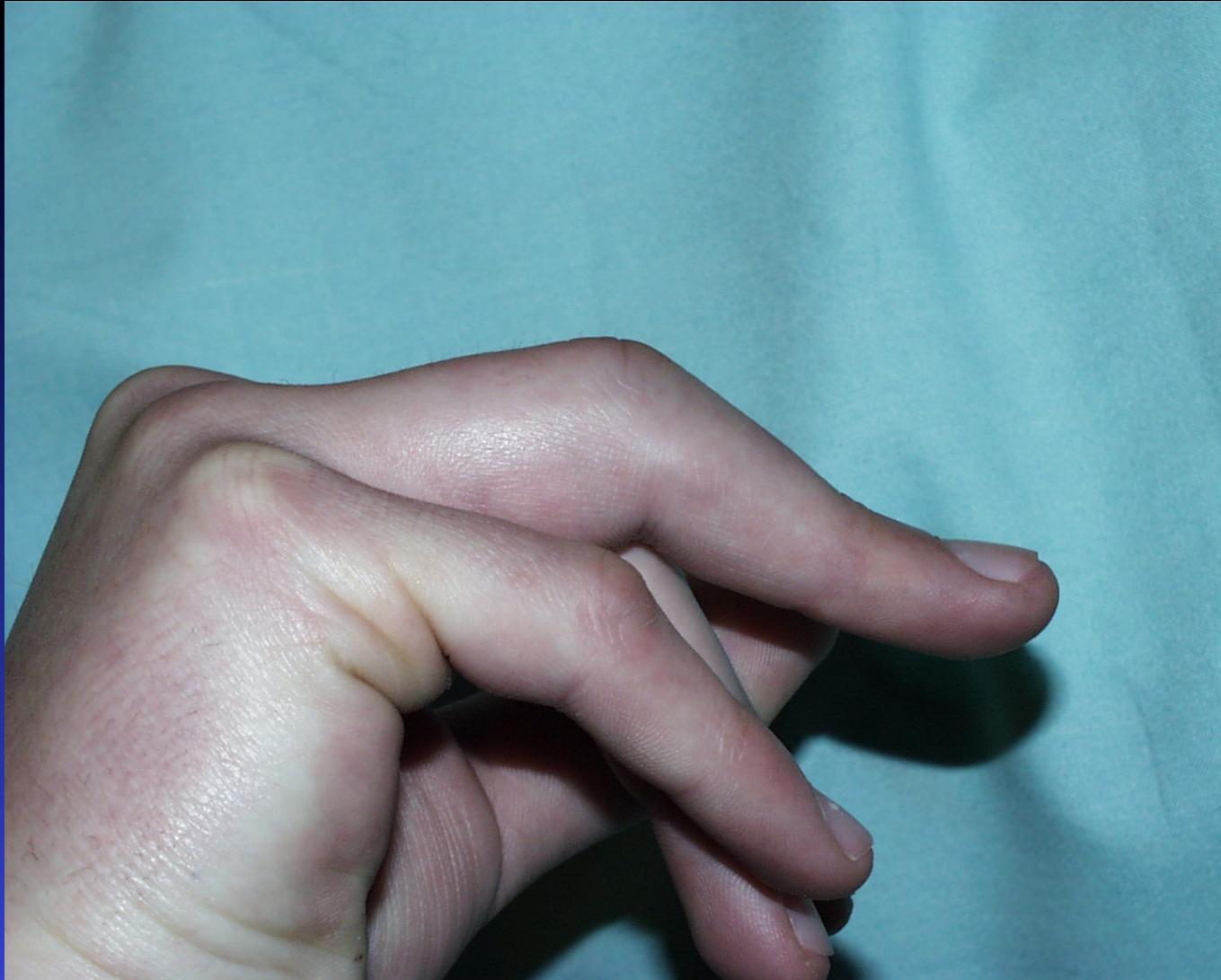

1. This child presents with a seizure
- what is the diagnosis?

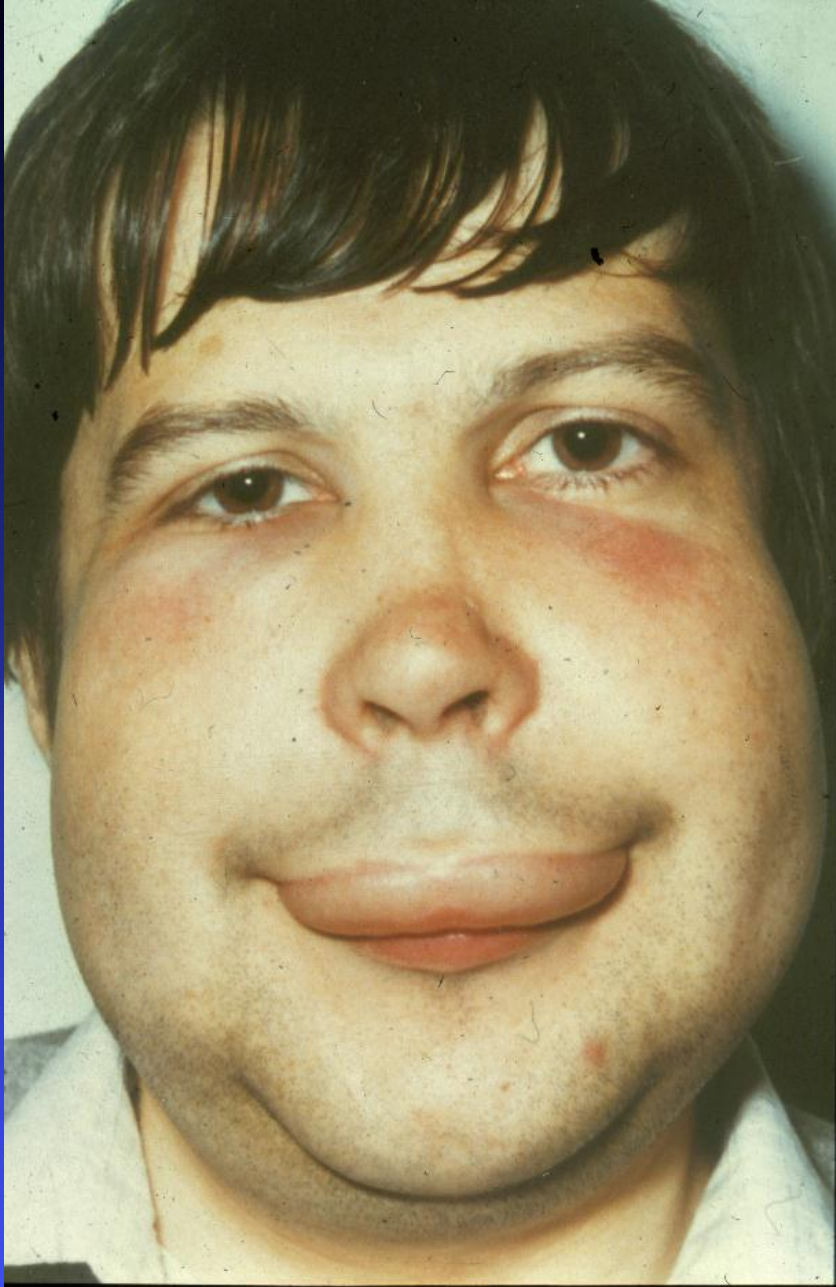



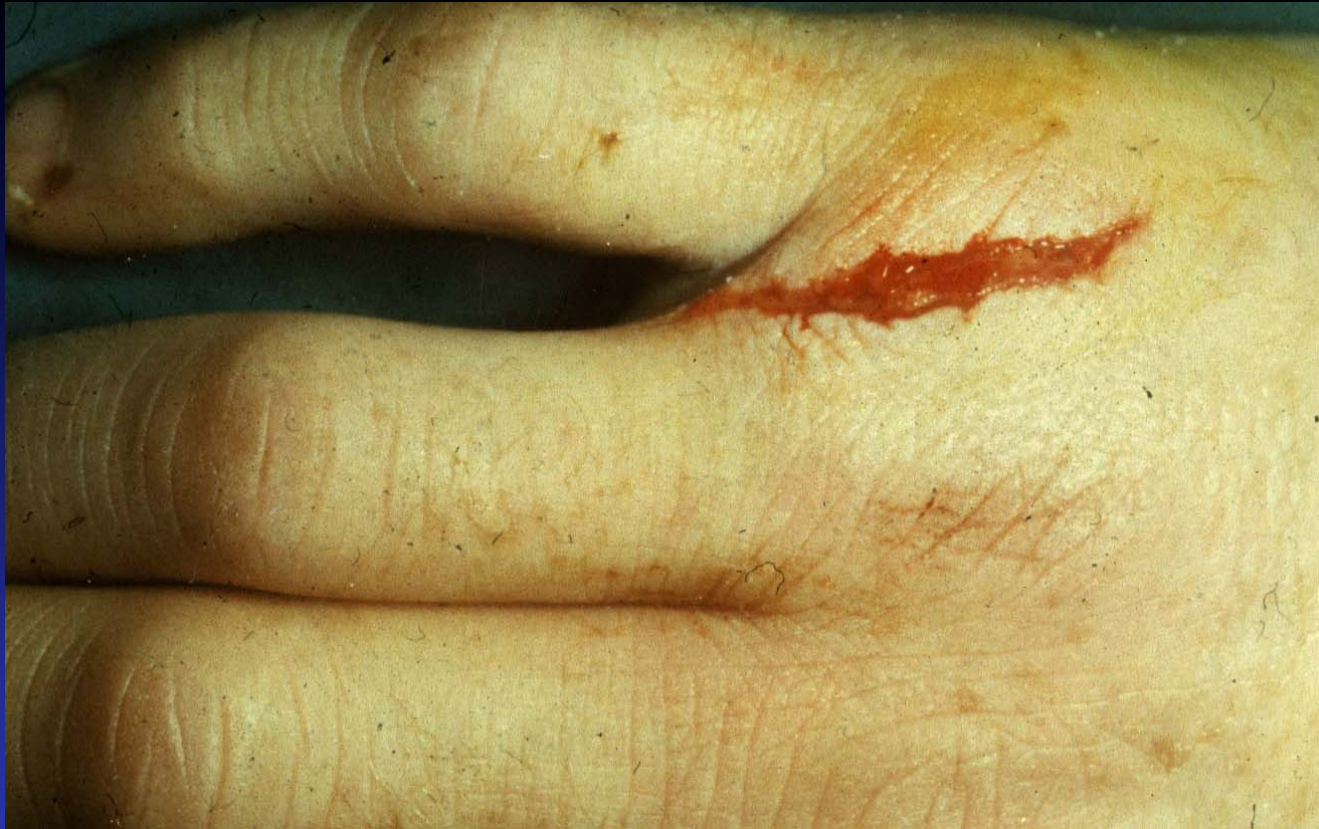1. This patient has fallen on his shoulder – how can this injury be classified ?
2. List the anatomical structures involved in the different classes of injury ?



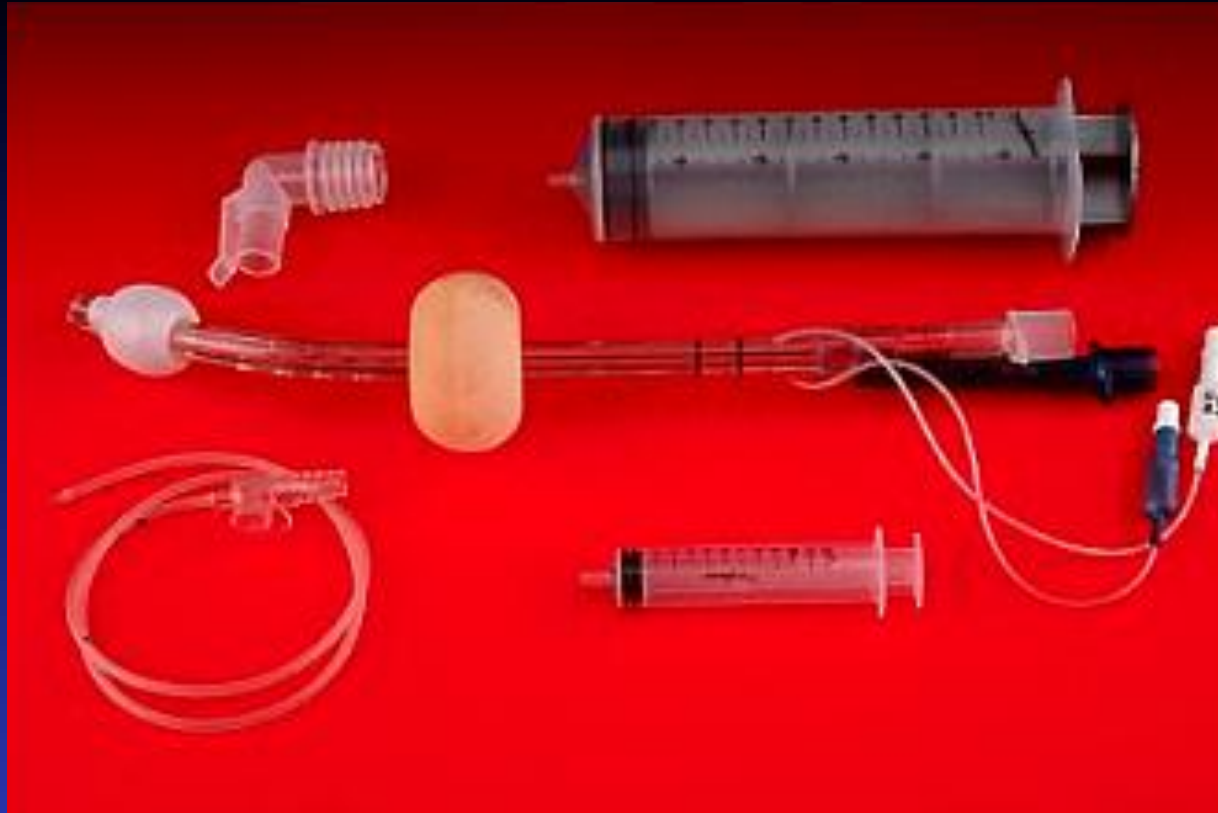1. What is this deformity known as ?
2. What anatomical structure has been injured to cause this deformity ?



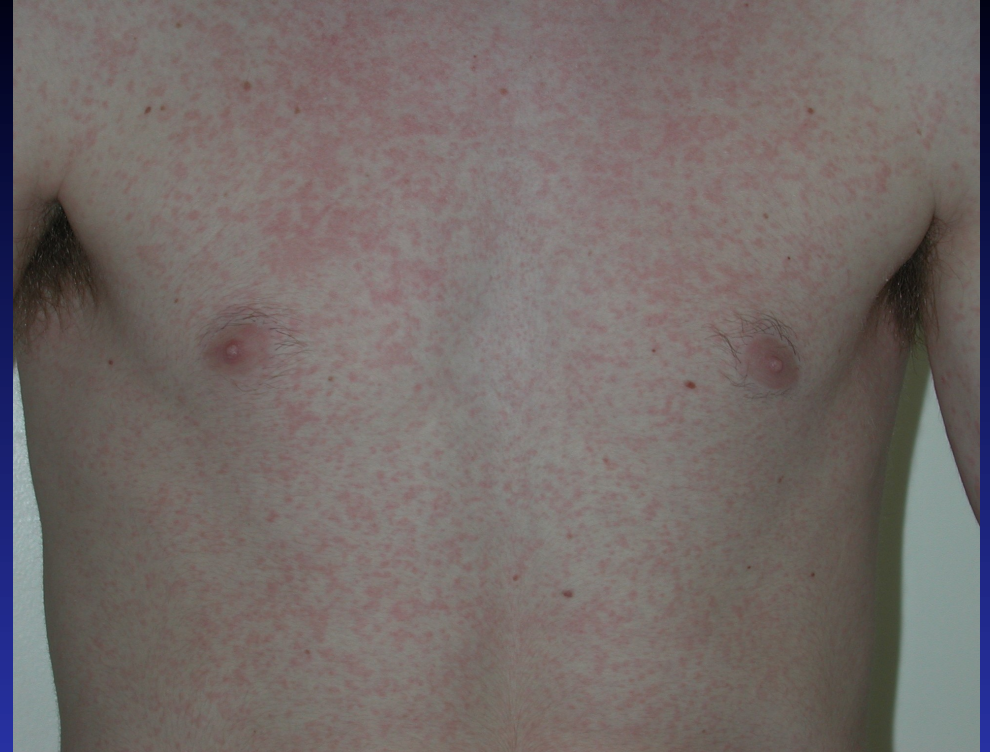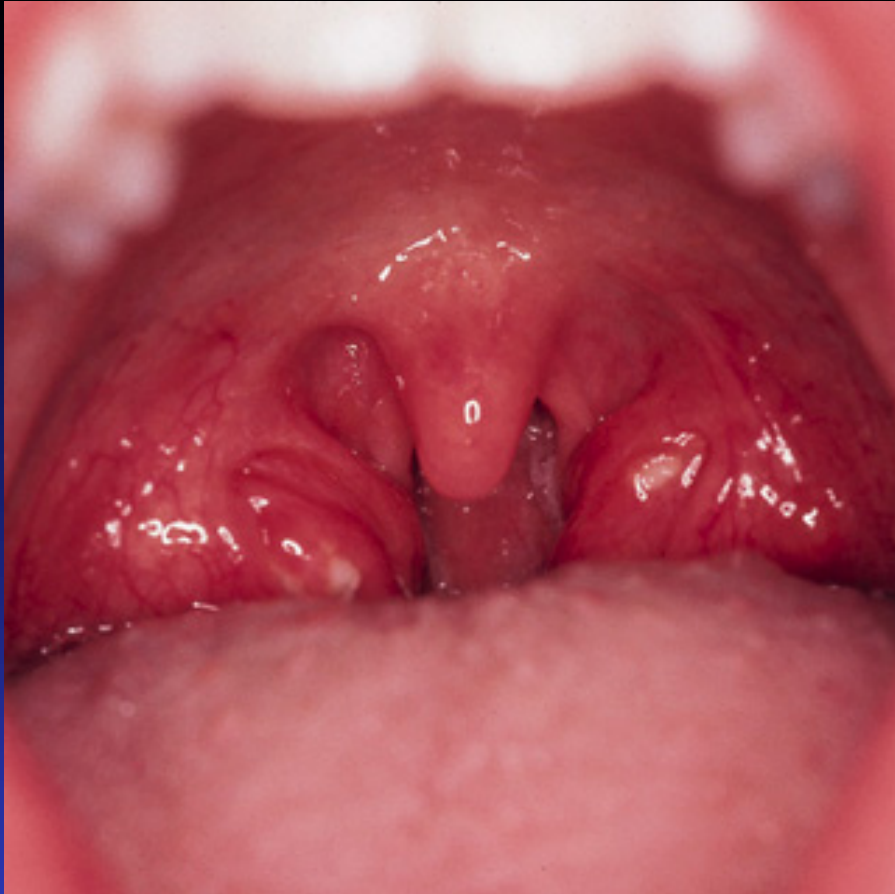1. This patient's upper lip has suddenly swollen up – what are the possible causes ?
2. Which class of drugs may cause this problem?



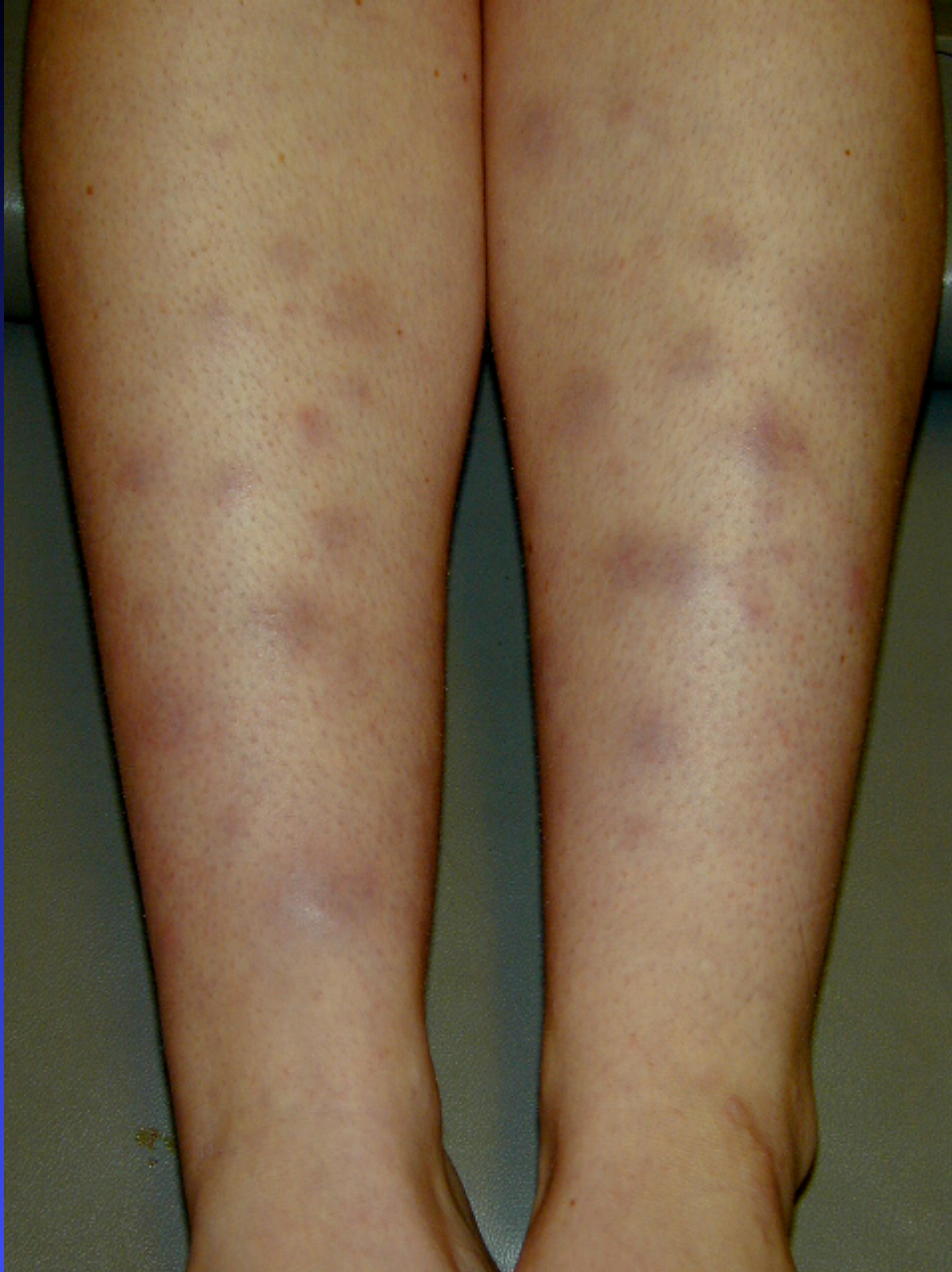
1. This patient has punched another person in the mouth and sustained this injury - what investigations are necessary ?
2. How would you treat this injury ?



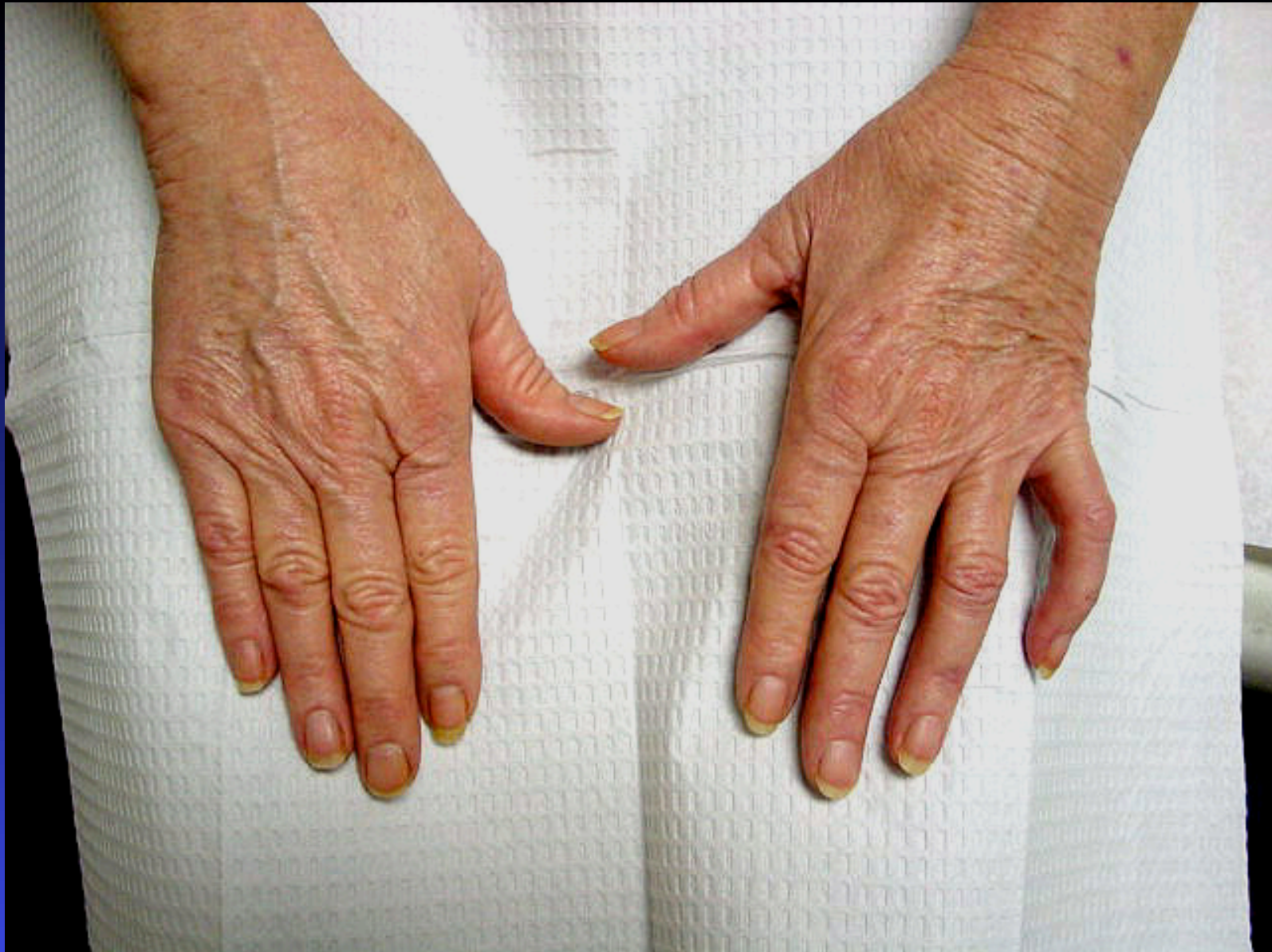
1. What is this piece of equipment ?
2. In what situation should it be used in the Emergency department ?



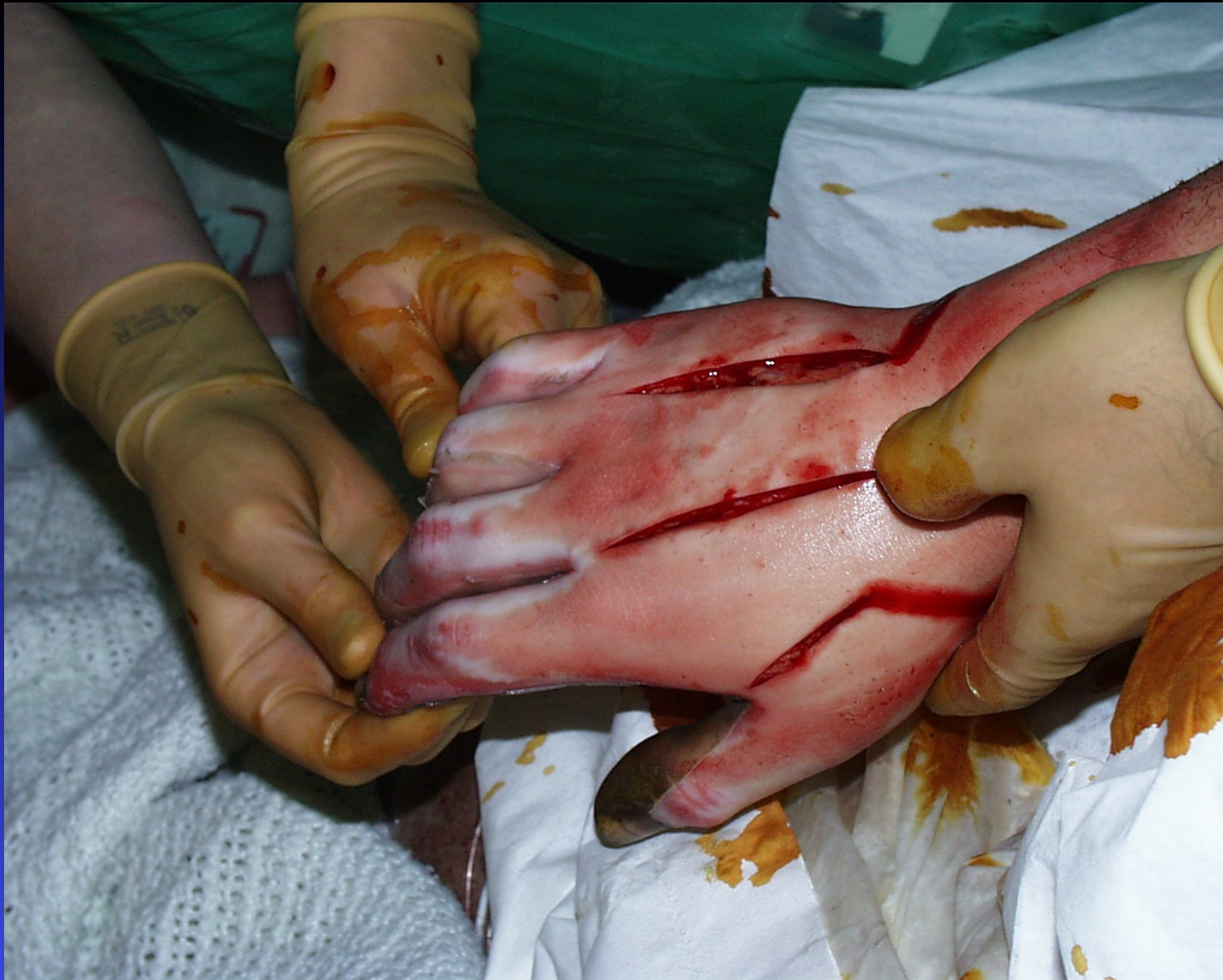1. This patient saw their GP with a sore throat and lethargy and was given penicillin. They have now developed a rash - what investigation is necessary ?



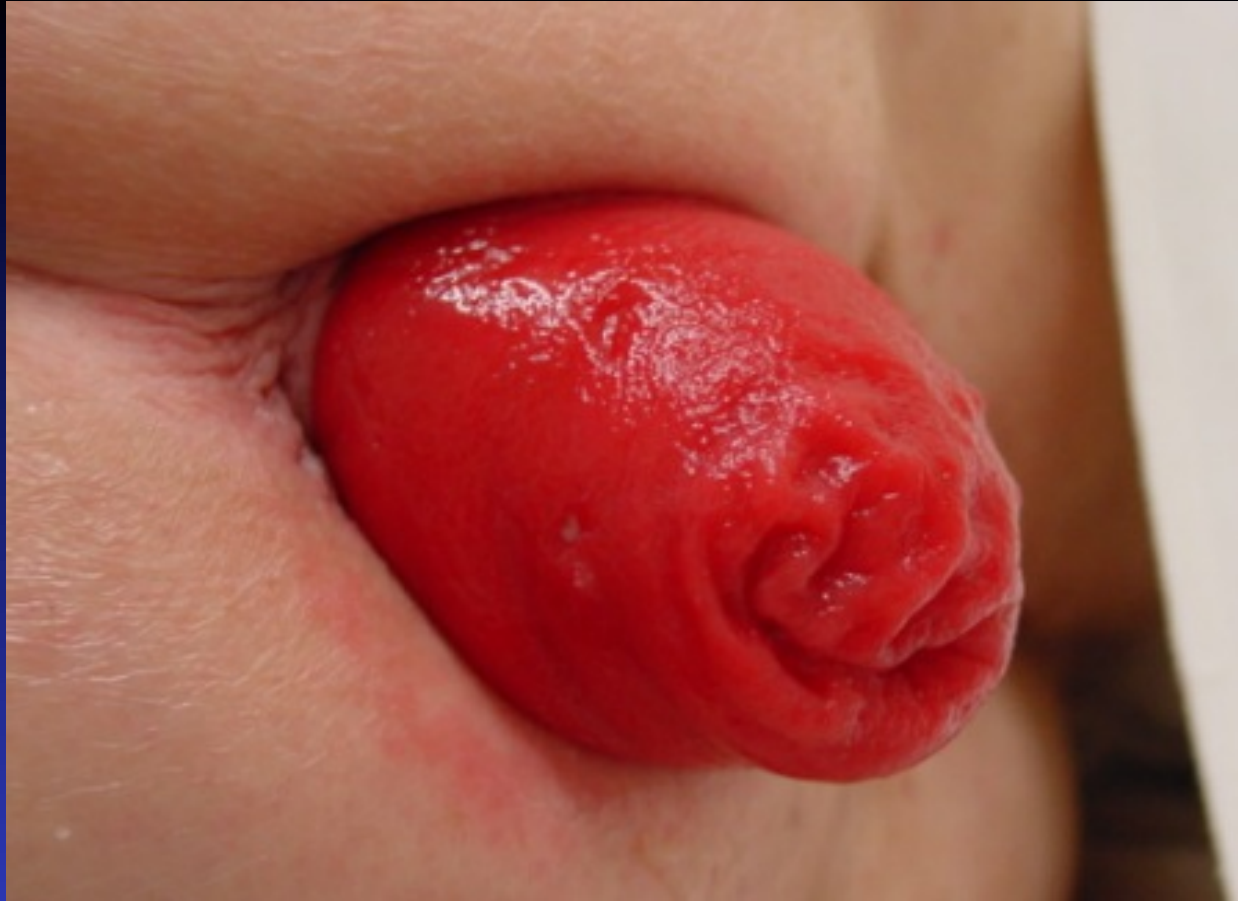1. What is the diagnosis ?
2. Give 5 causes of this rash ?



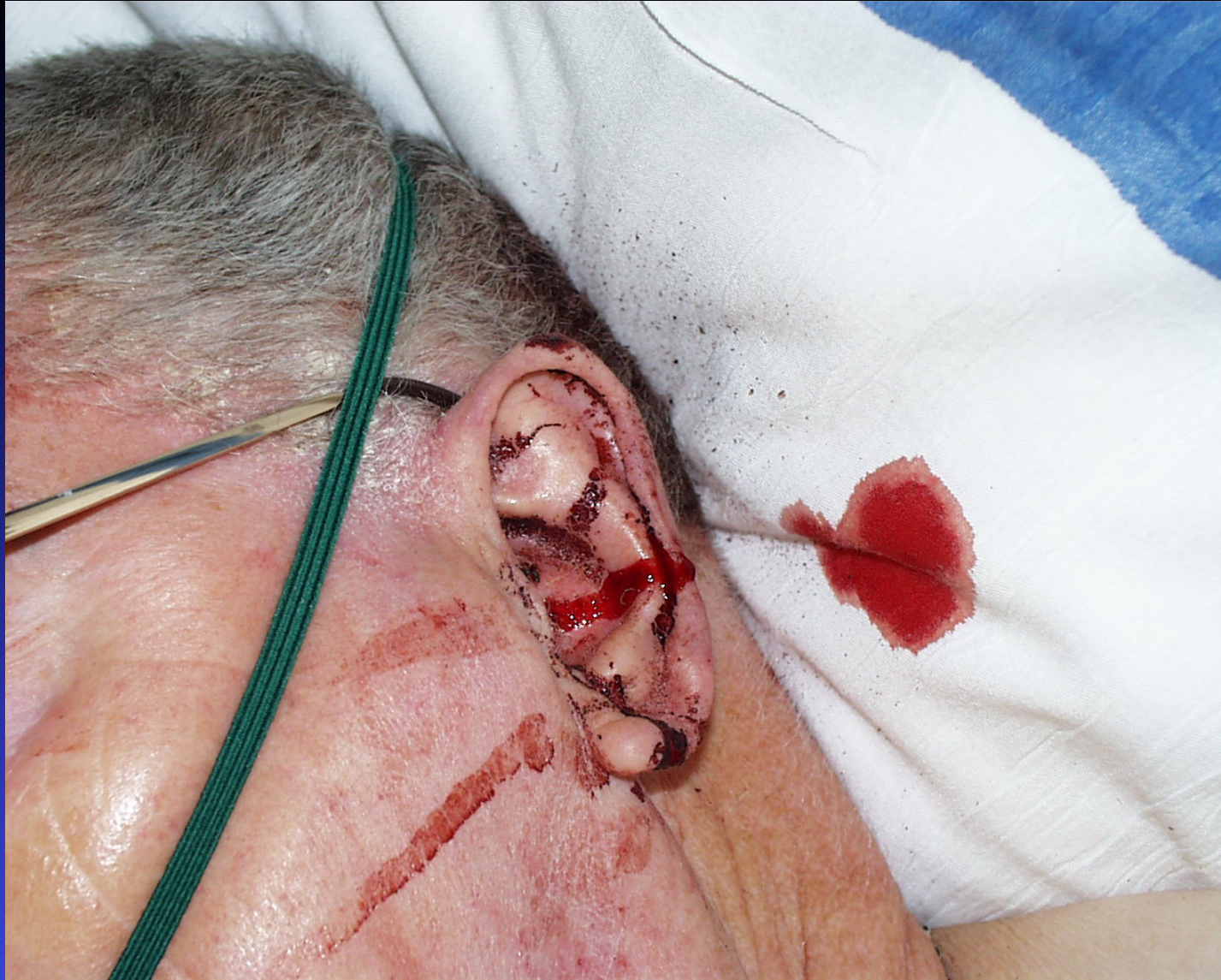1. Why is this patient complaining of weakness and sensory loss in their left hand ?
2. What are the possible causes of this problem ?



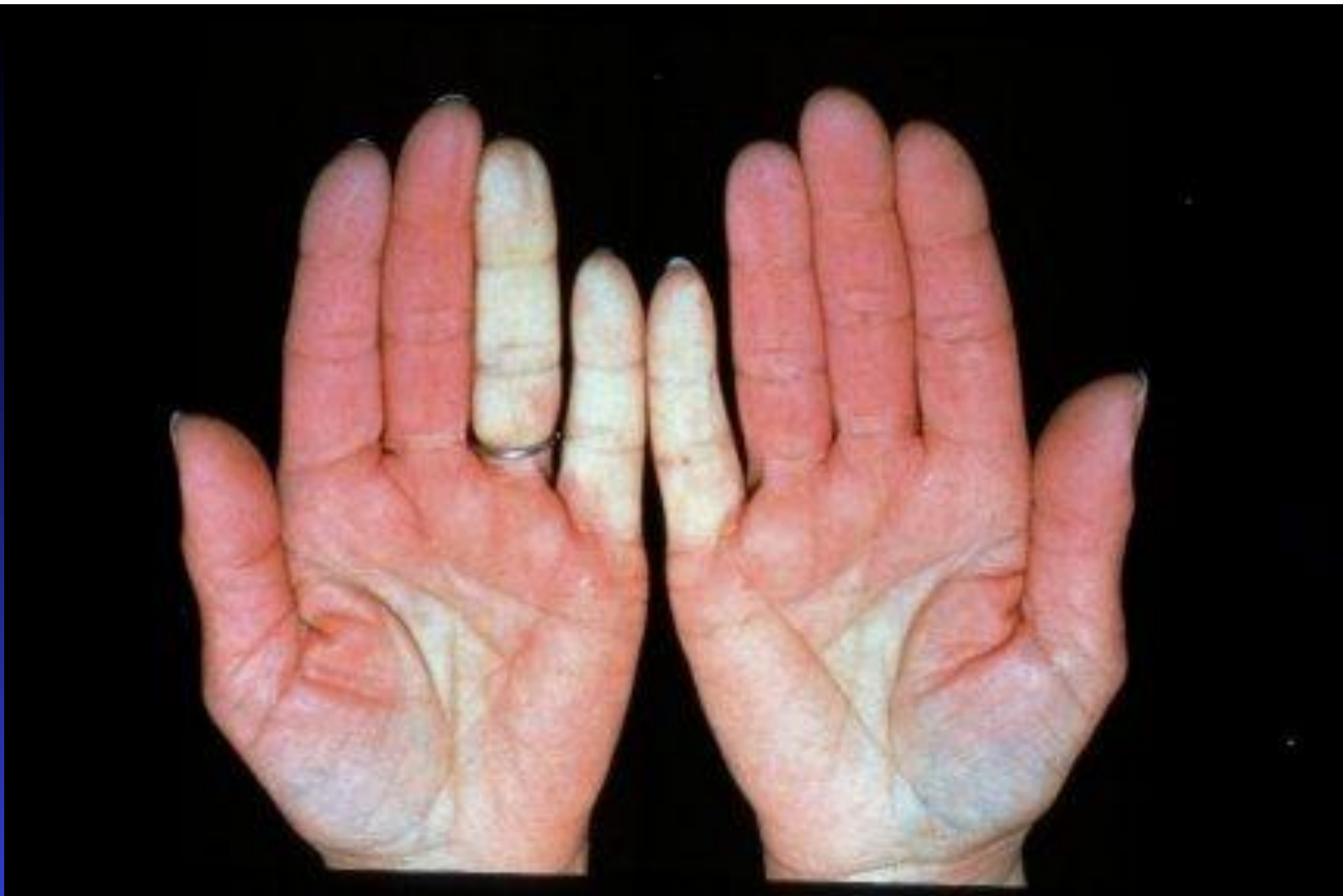
1. What procedure is being carried out ?
2. Why was it deemed necessary ?



1. What is this problem and what treatment is necessary ?



1. What is this clinical diagnosis ?
2. What neurological complications are associated with this injury ?



1. What is this condition known as ?
2. What systemic conditions is it associated with ?

Any Questions ?