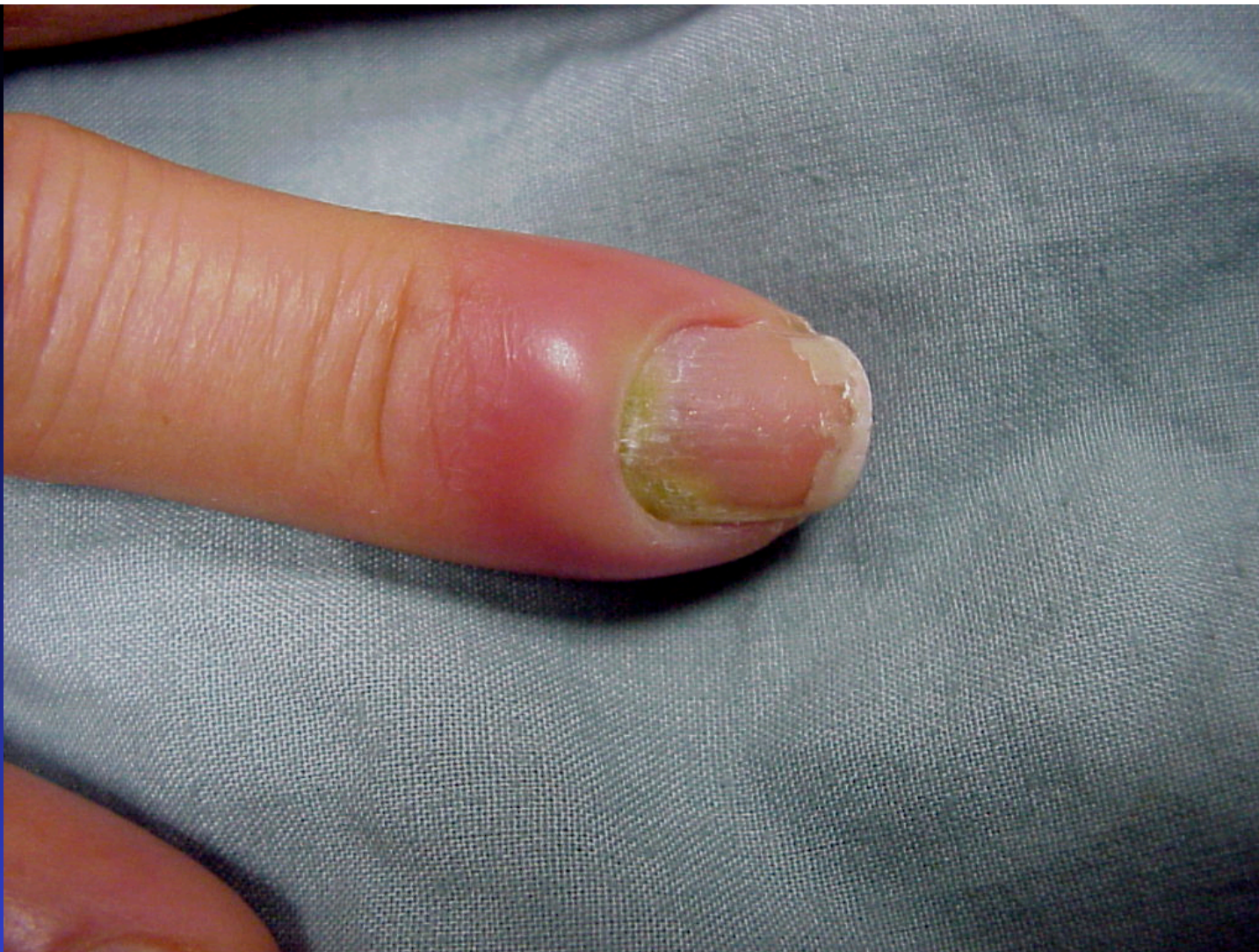
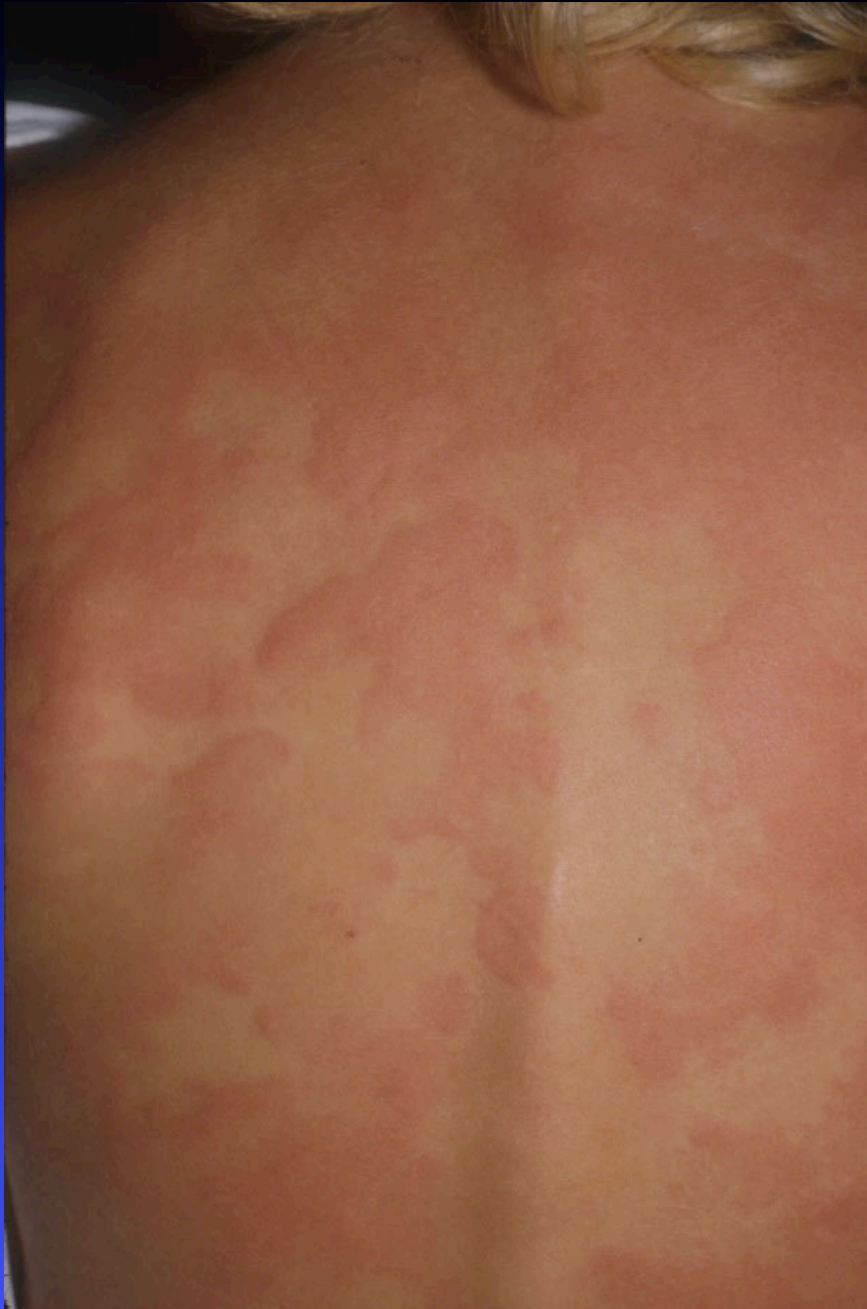


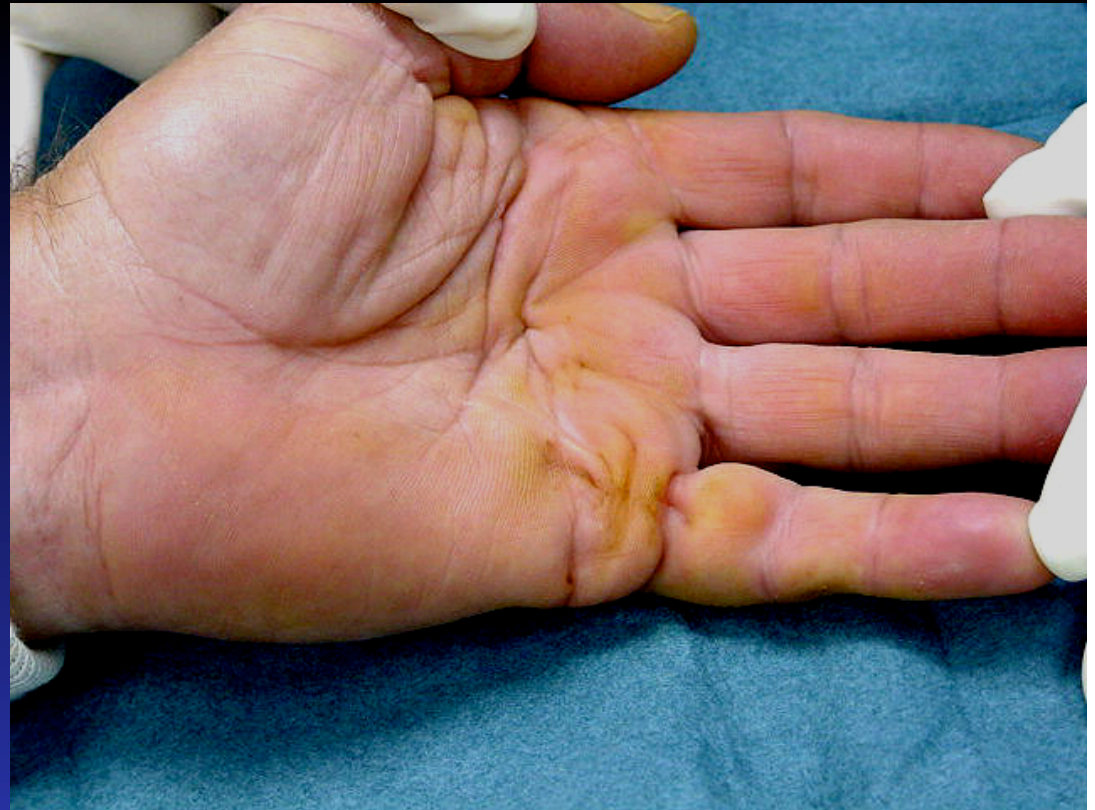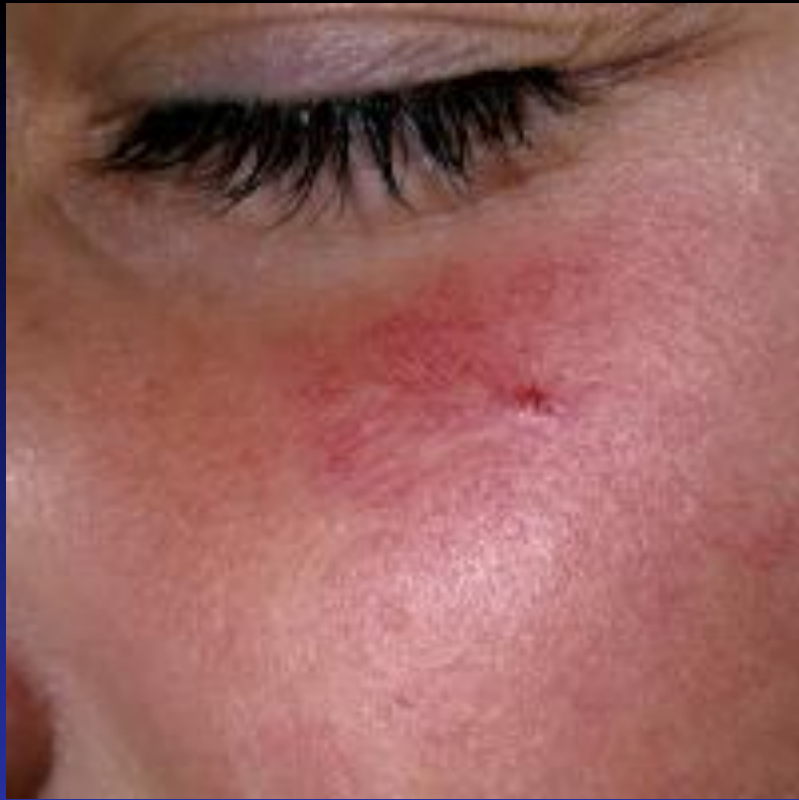Picture Quiz 4



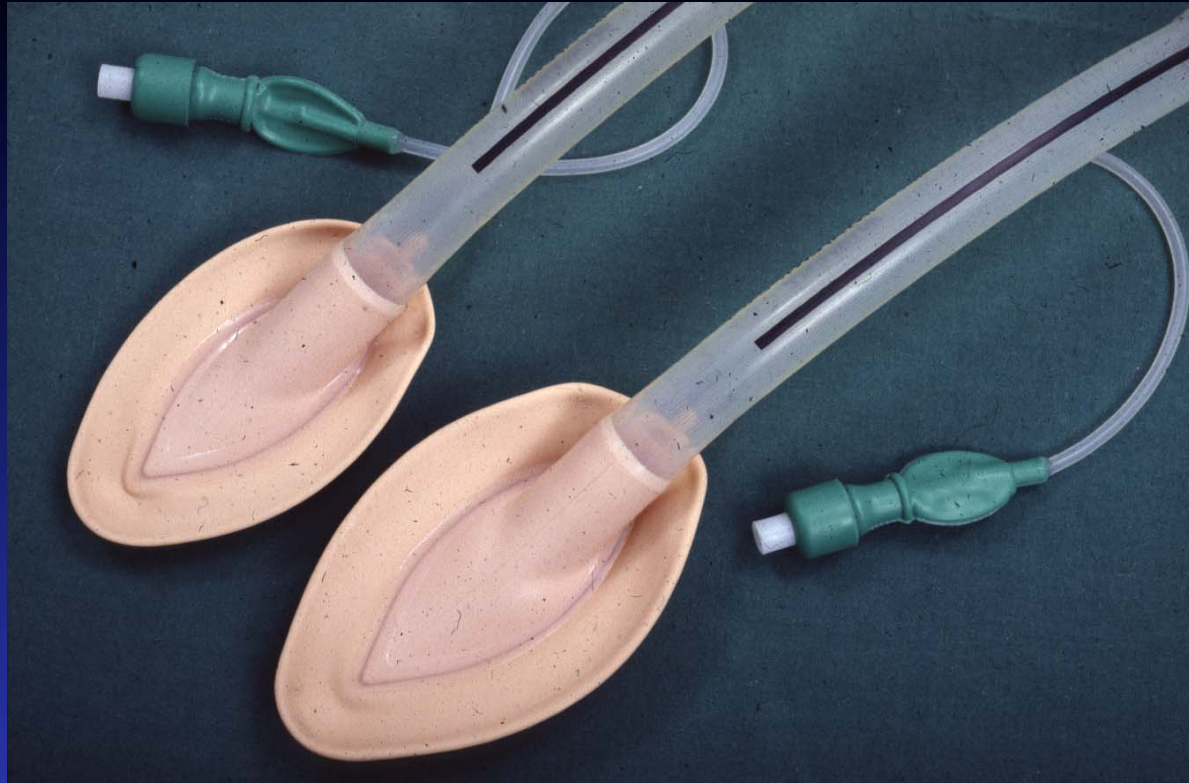
1. What is the diagnosis ?
2. How would you manage this patient ?



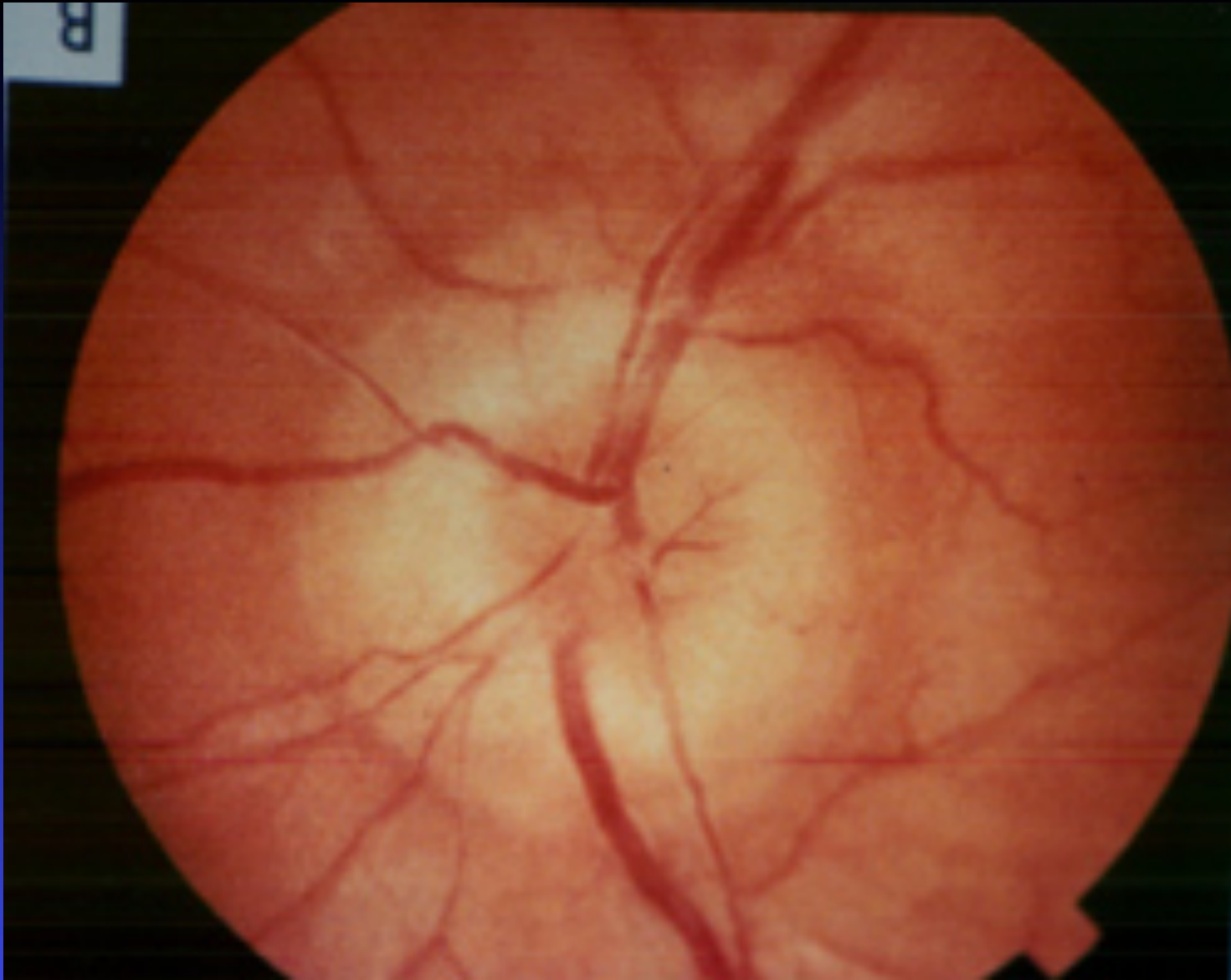1. This itchy rash has just appeared on this patient's back – what is the diagnosis ?
2. Give 3 causes for this rash



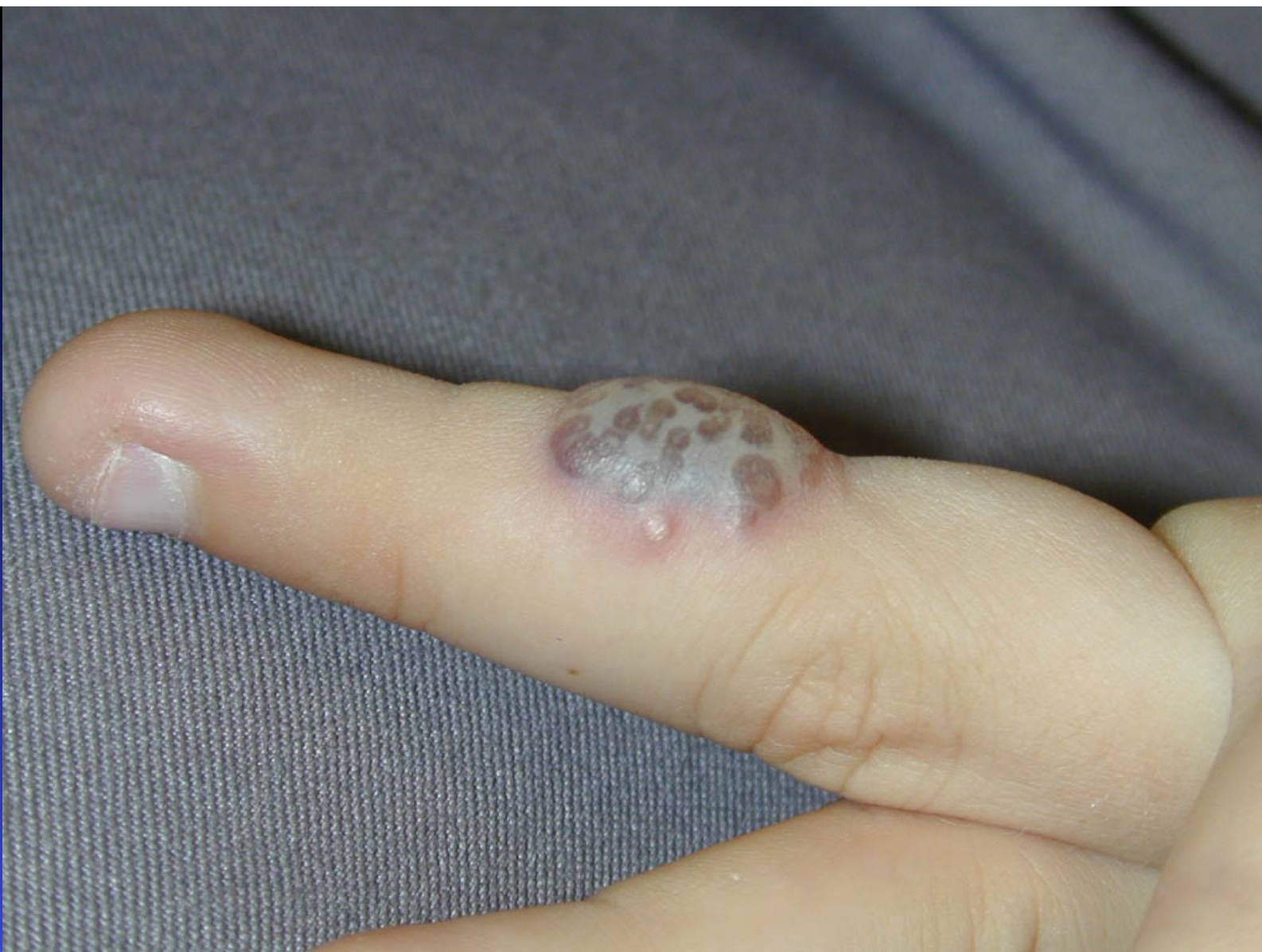1. What are these abnormalities known as ?
2. What other abnormalities would you look for on examination ?



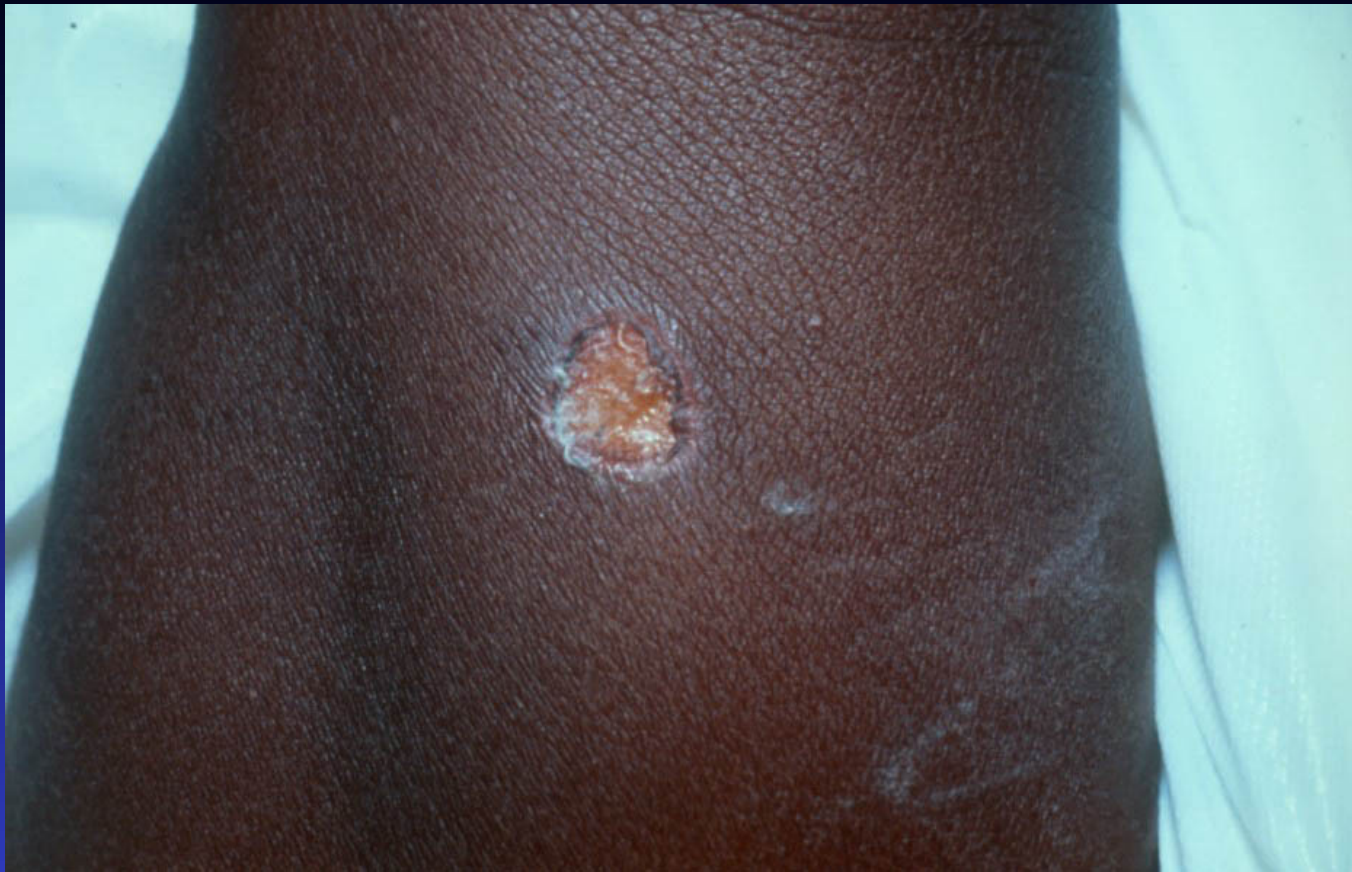
1. What is this piece of equipment ?
2. In what situation should it be used in the Emergency department ?
3. How would you decide which size to use ?



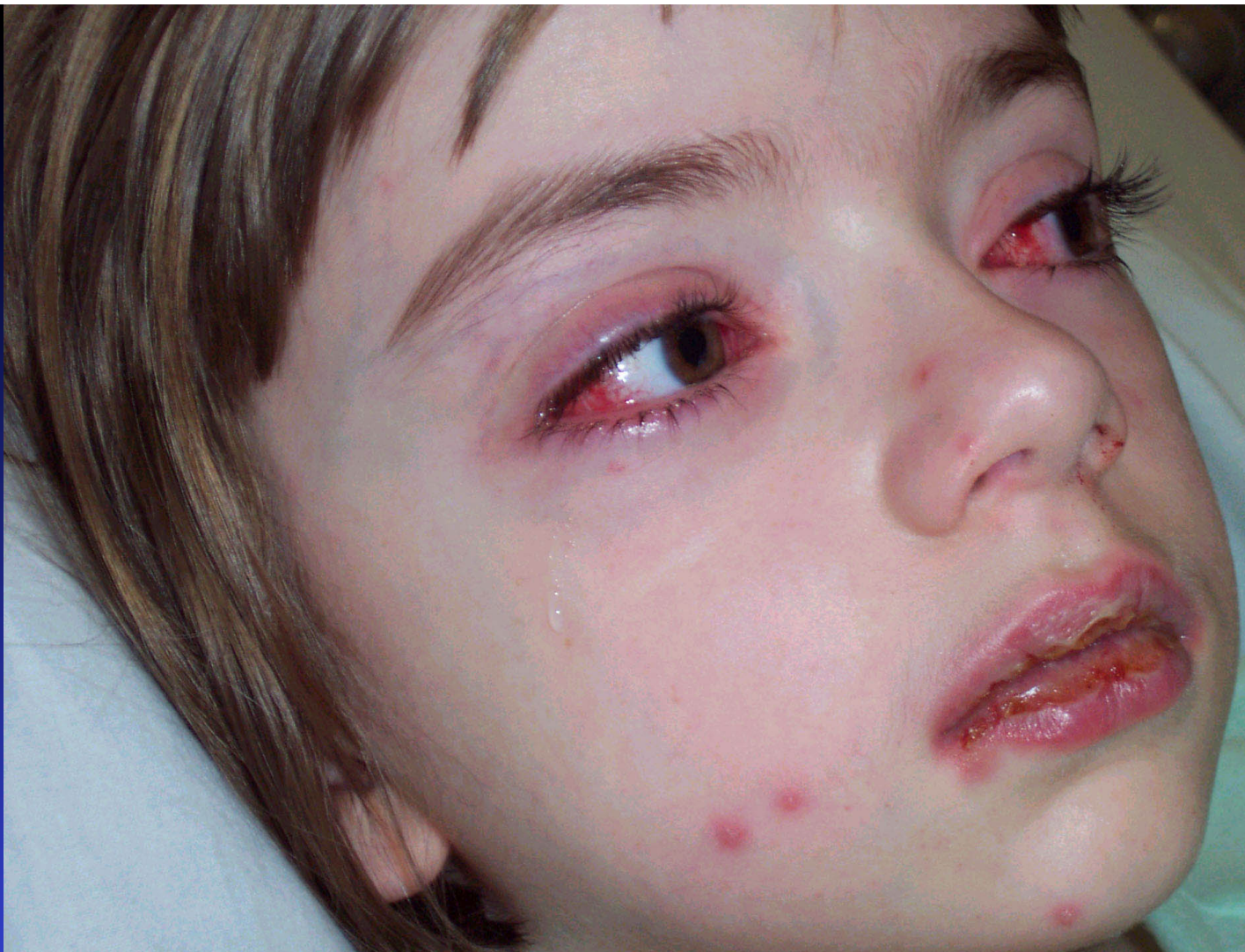1. This young woman presents with increasing headaches. There is no history of trauma. What is the differential diagnosis ?



1. What is this lesion ?
2. How should it be managed ?



1. A child has been brought to the Emergency department with this unexplained lesion. What are the possible causes ?
2. What features of the history would alert you to the possibility of non-accidental injury ?



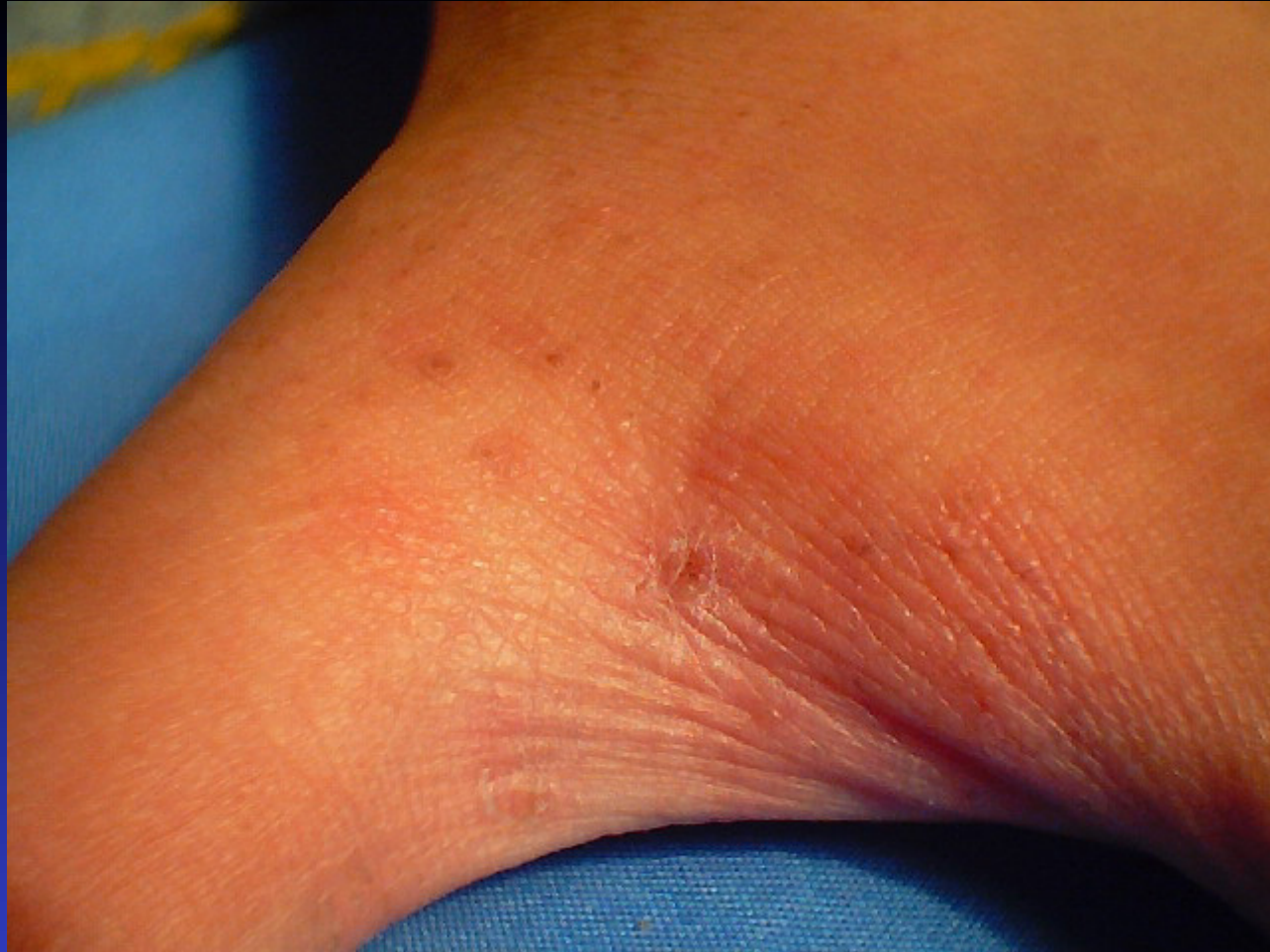
1. What is the diagnosis ?
2. List 4 causes and indicate the initial management of this problem ?



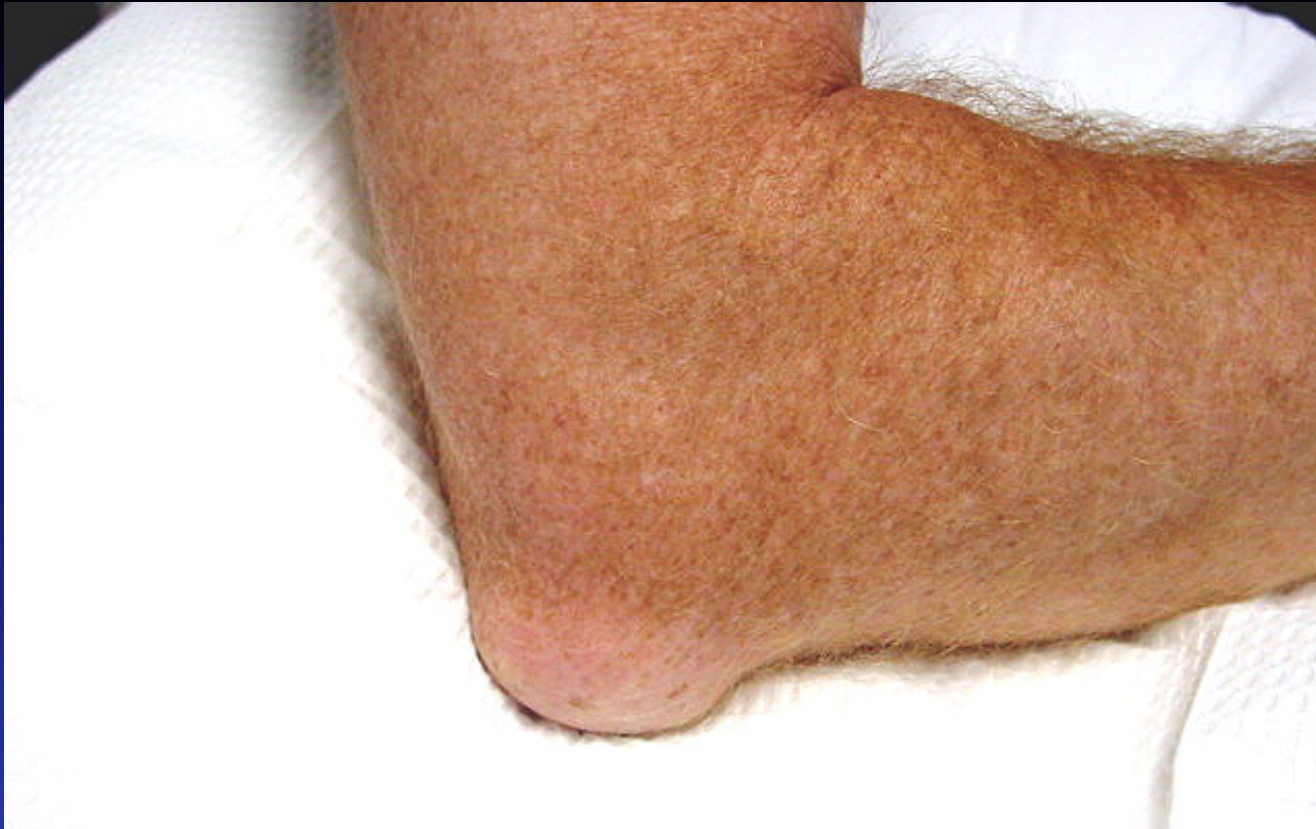1. How would you remove this object ?



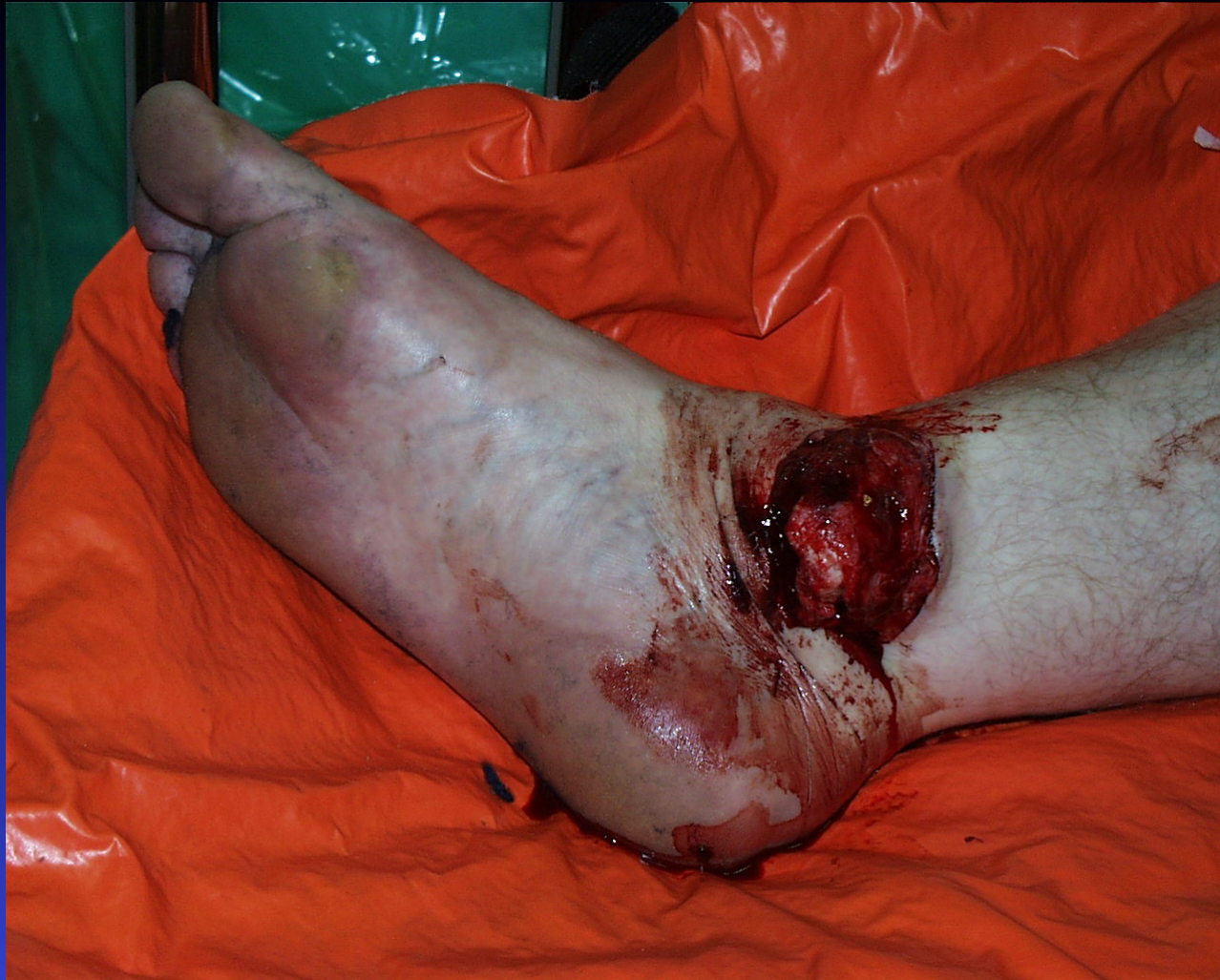1. This fluid has just been aspirated from an acutely injured knee joint. What is the cause of this appearance and what is its significance ?



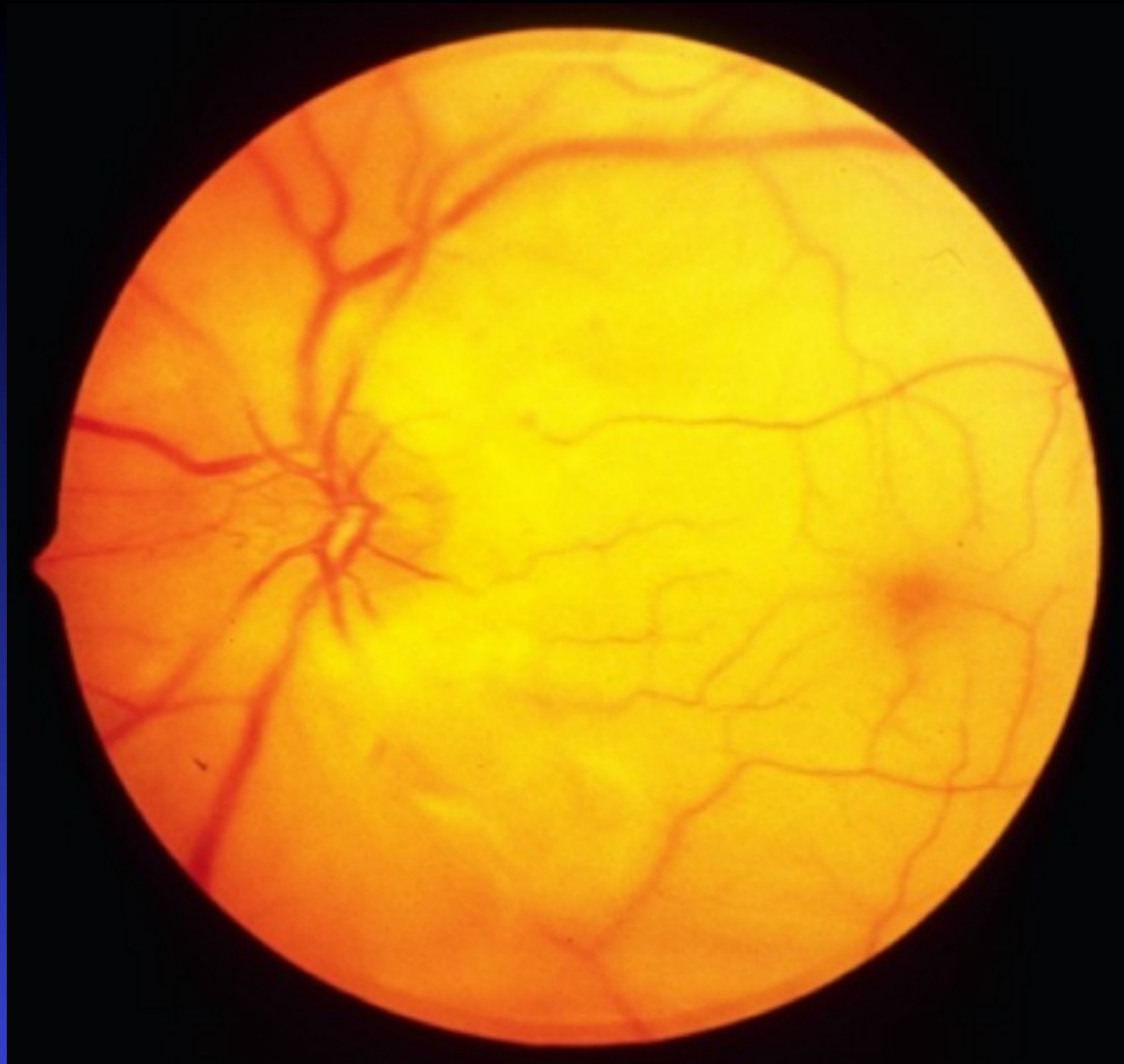
1. What is the cause of this intensely itchy lesion in the 1st web space ?
2. What treatment is required ?



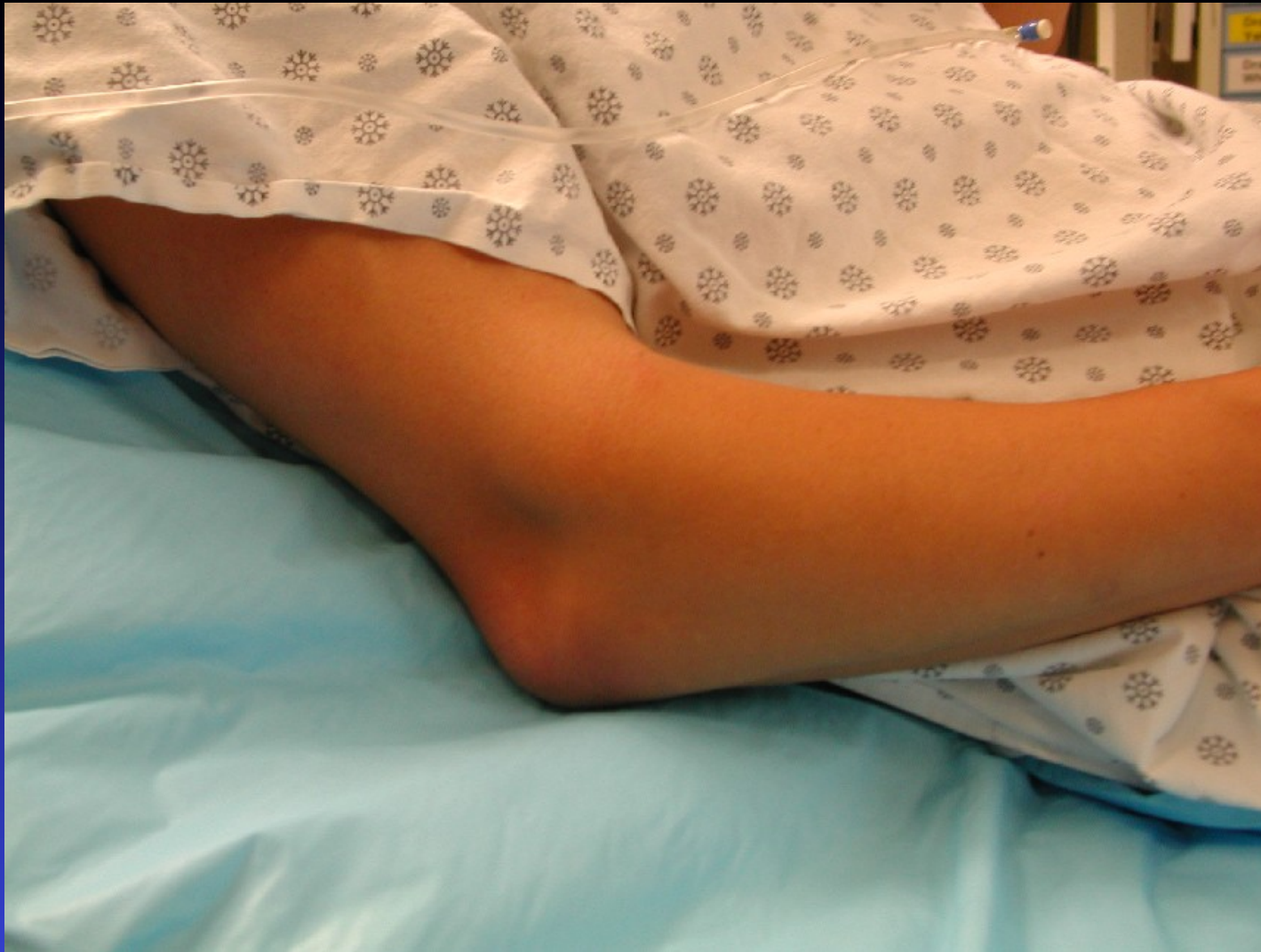1. What is the management of this fluid filled swelling ?



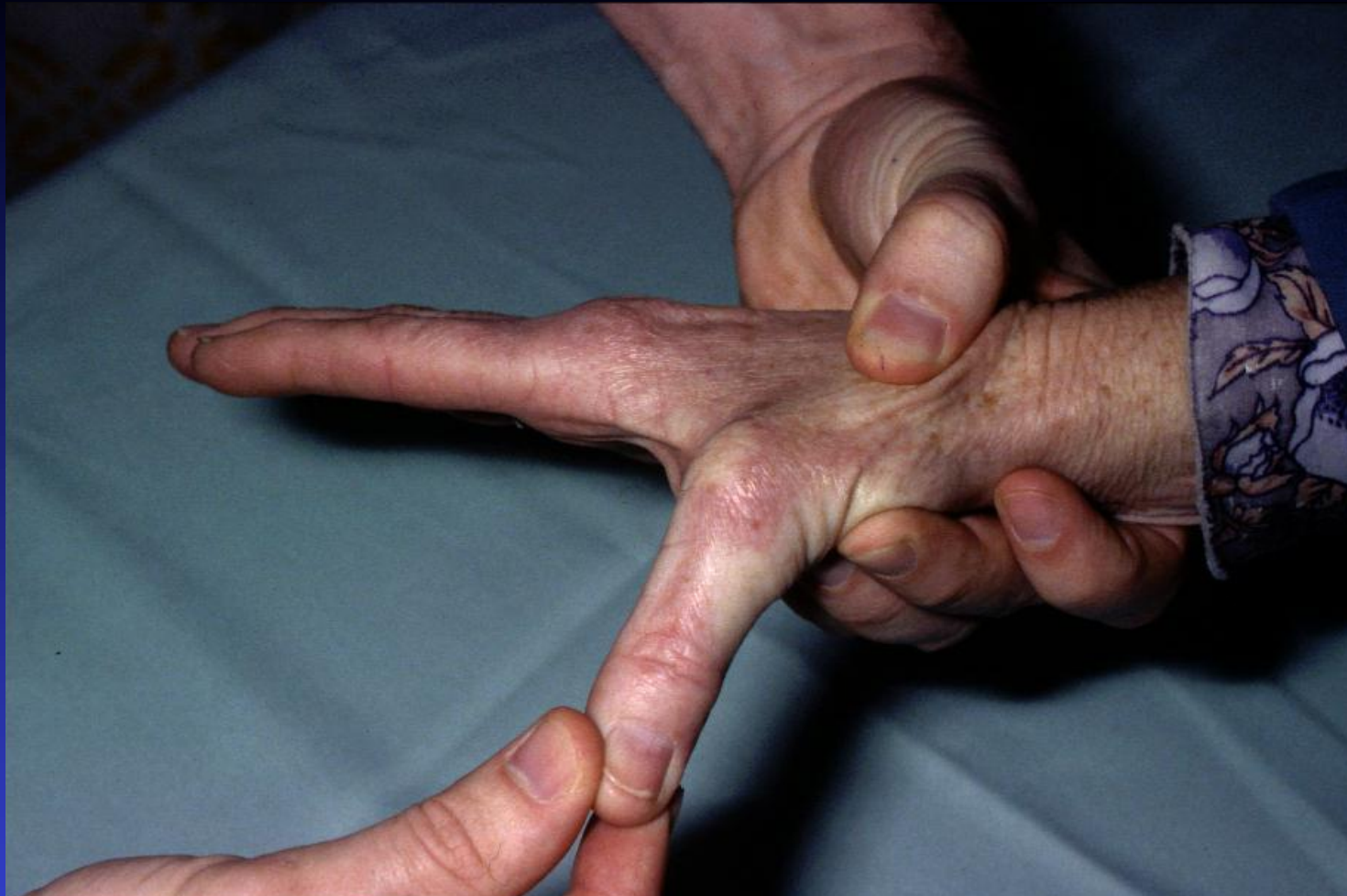1. What are the priorities in the management of this injury ?



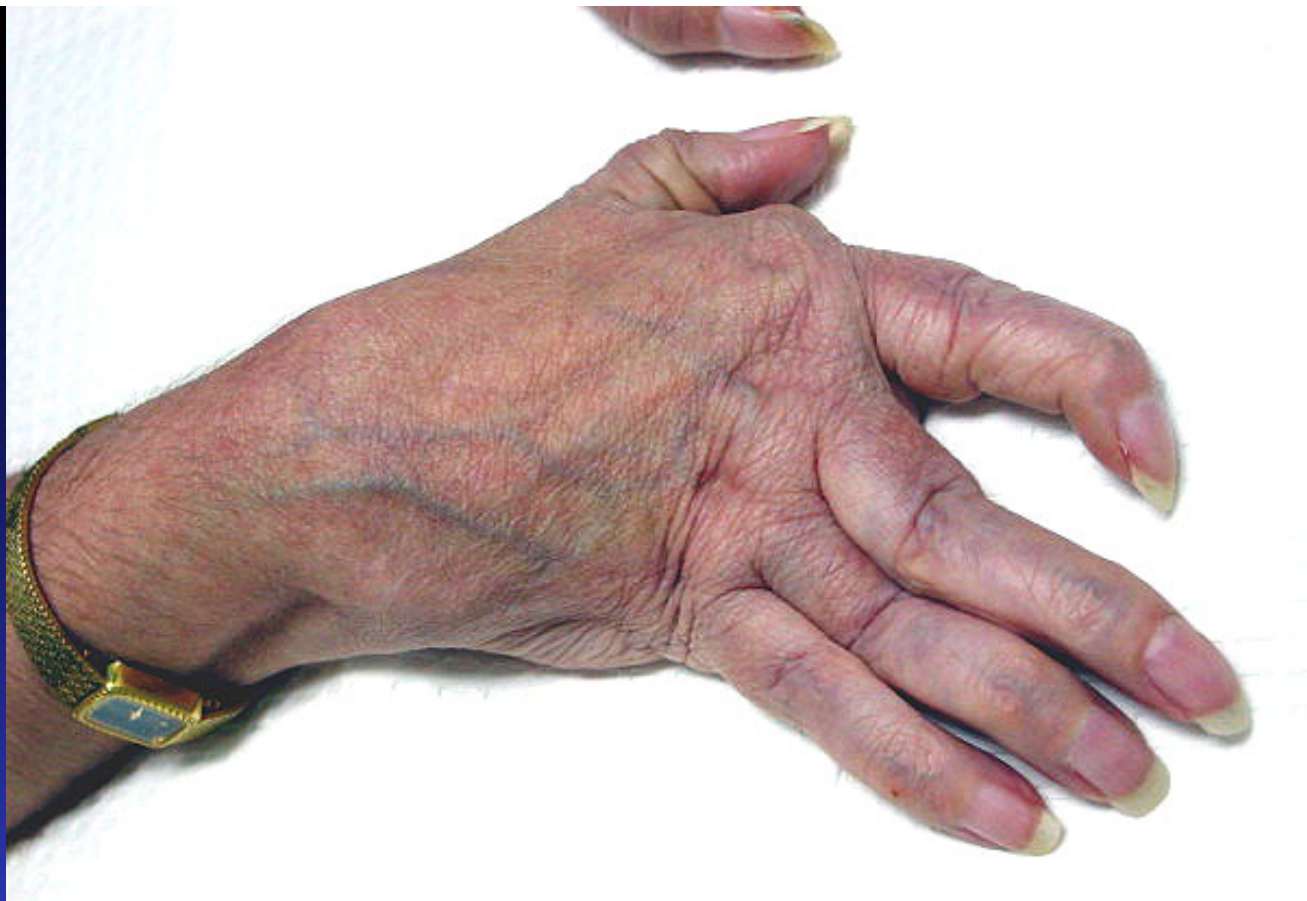1. Why has this patient experienced a sudden loss of vision ?
2. What is the Emergency department management of this problem ?



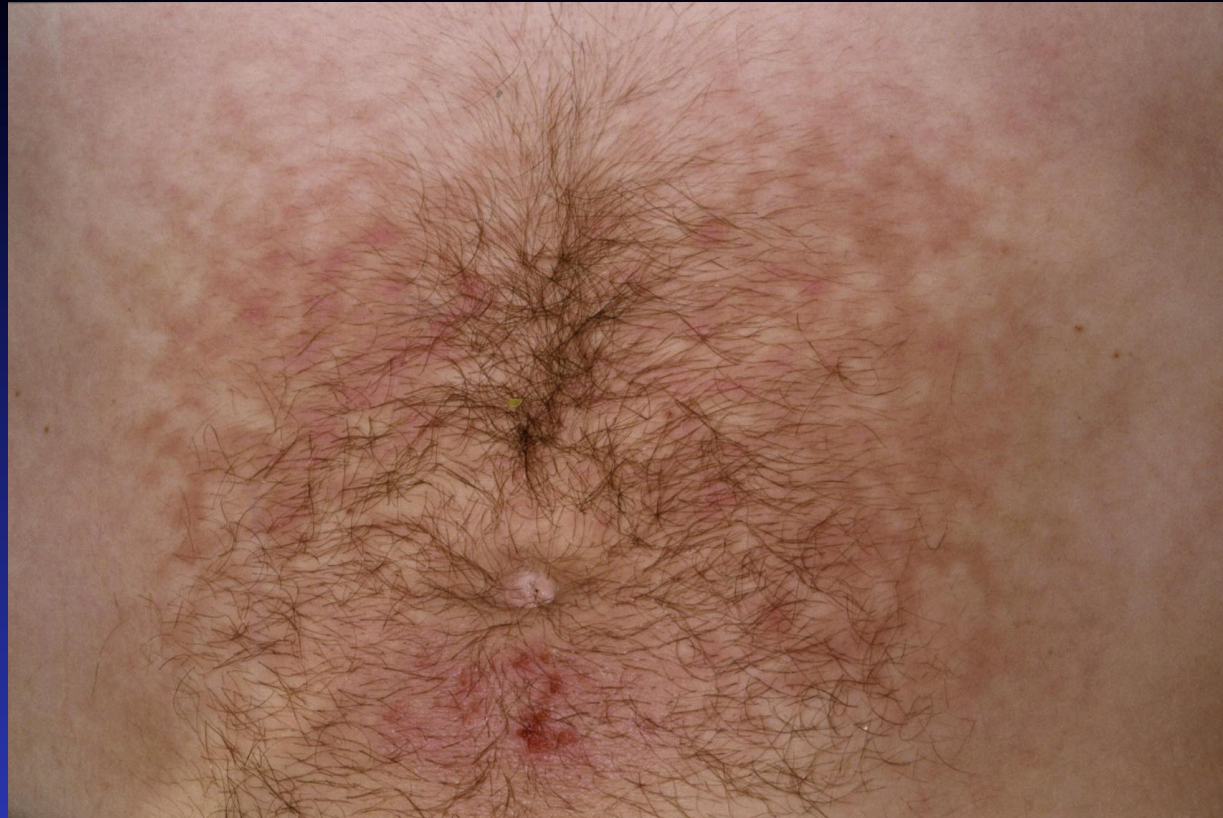1. What injury has this patient sustained ?
2. What is the management ?



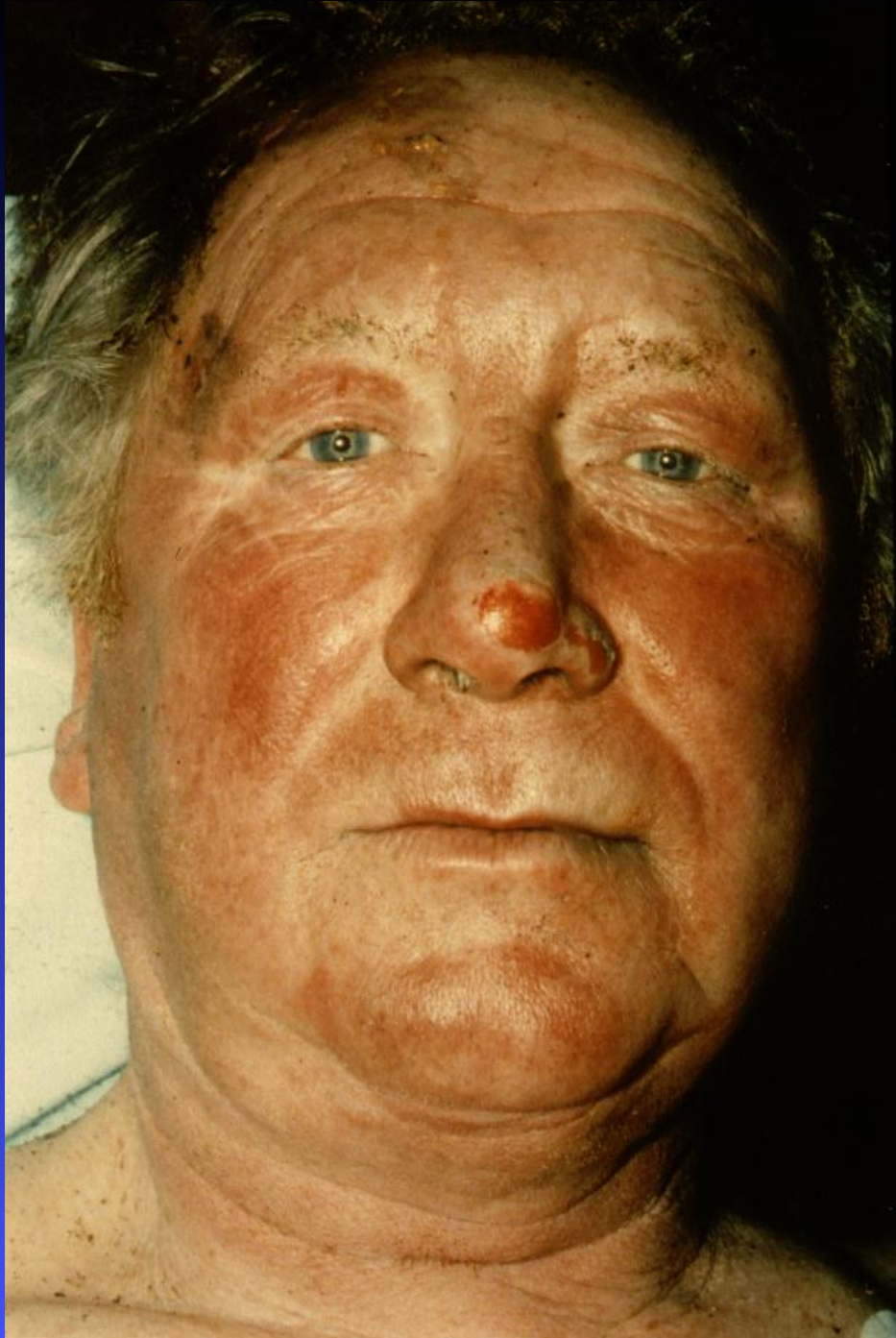1. What injury is being demonstrated here ?
2. Why do the majority of these injuries need operative repair ?



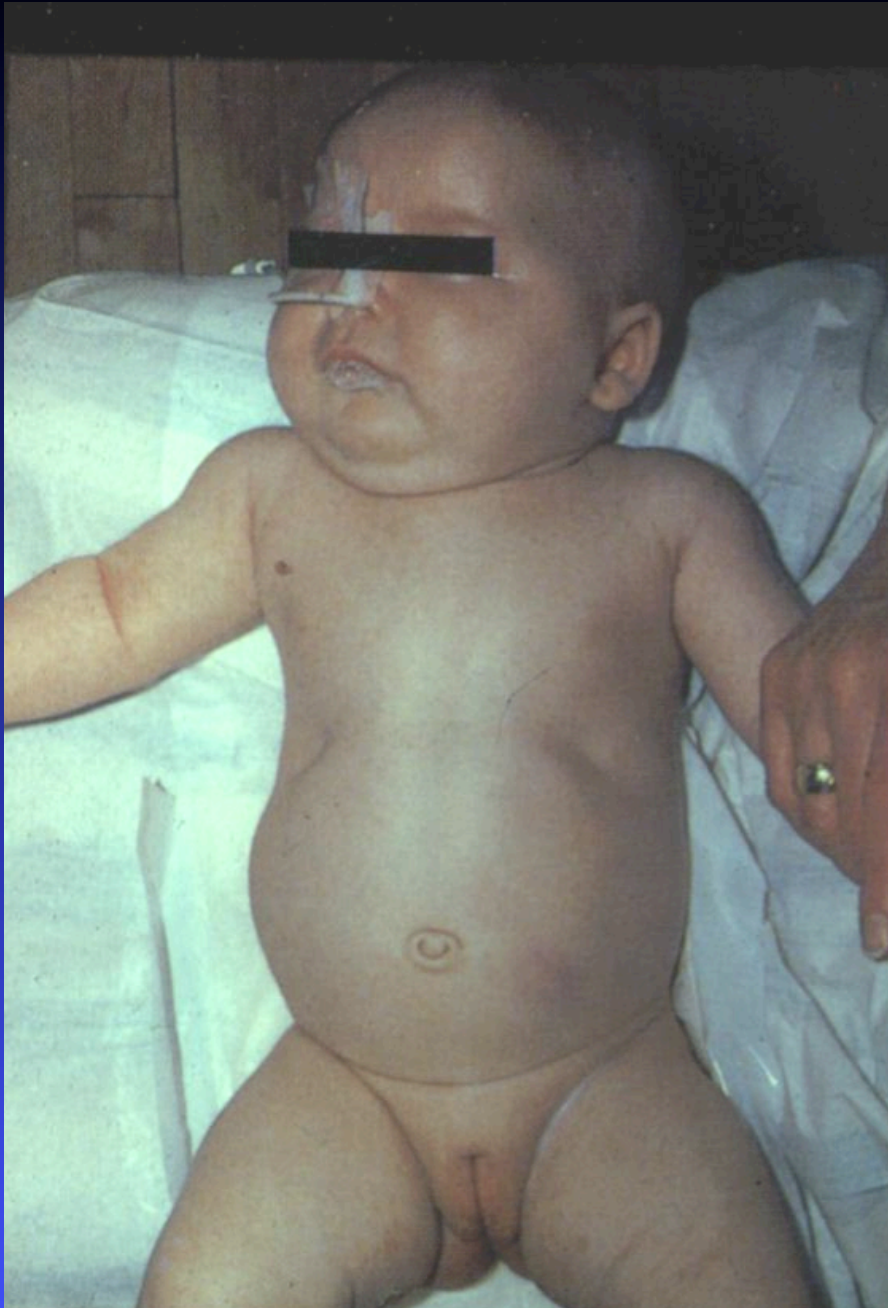1. What is the diagnosis ?
2. This patient has been involved in a rear shunt RTA and complains of neck pain – should you be concerned and why ?



1. What is this rash on this patient with abdominal pain ?



1. This patient has been exposed to a sudden flash of hot gases – what significant findings would you look for on examination ?
2. How should this patient be managed ?



1. How would you assess this breathless infant ?

Any Questions ?