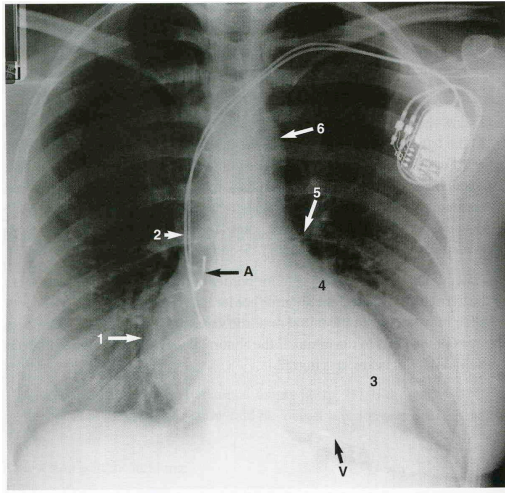


Chest X-ray



PART 1

On the above CXR, name the anatomical features numbered (3 marks)

- 1 *R Atrium*
- 2 *Superior vena cava*
- 3 *Left ventricle*
- 4 *left atrial appendage*
- 5 *pulmonary artery*
- 6 *aortic knuckle*

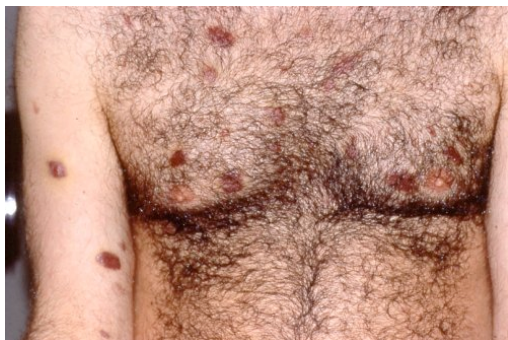PART 2

A 26 yr old male attends A&E complaining of a cough for the past 3-4 weeks, and now increasing shortness of breath. He says he has been told to attend by his wife because he is too short of breath to work. He is an air steward. PMH and DH nil.

On examination

Hr 96 regular HS 1+2 + nil
RS AE al zones, nil added
RR 36
SaO₂ 89% on air

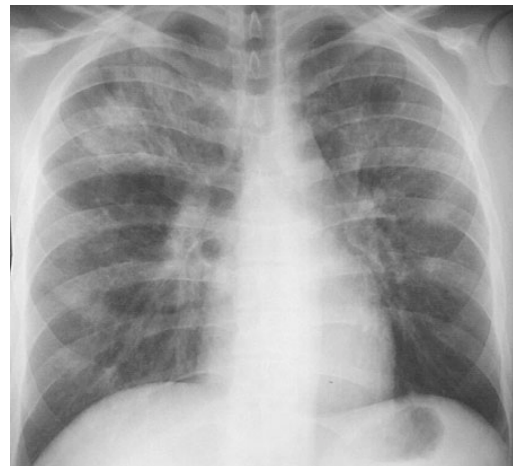You note these lesions on his chest



What other elements of history do you specifically require? (1 mark)

Sexual history, iv drug abuse

His CXR looks like this



What is the skin diagnosis? 1 mark
Kaposi sarcoma

What is the CXR diagnosis? 1 mark
Pneumocystis carinii pneumonia

What is the overall diagnosis? (2 marks)
AIDS with CD4 count < 200

Name 2 other conditions with which this illness might present (2 marks)
Oral candidiasis, CMV retinitis, lymphoma, M avium cellulare, TB, + many more