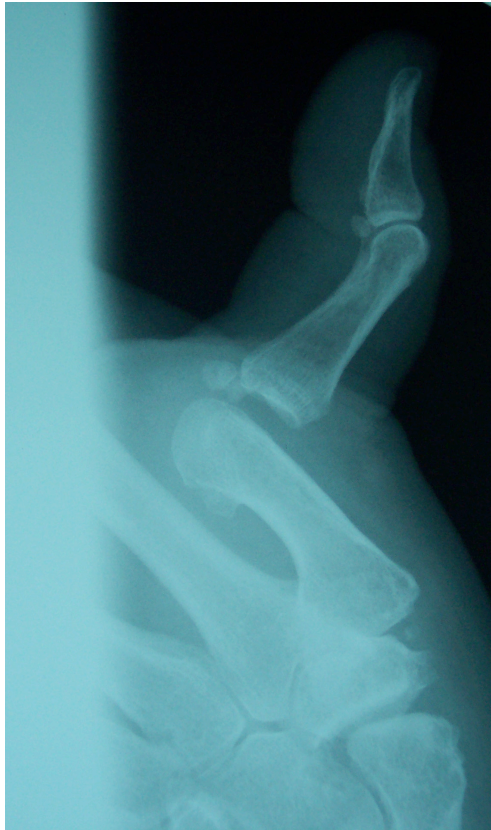

Describe this injury (1)

Posterior dislocation of the thumb at the metacarpophalangeal joint

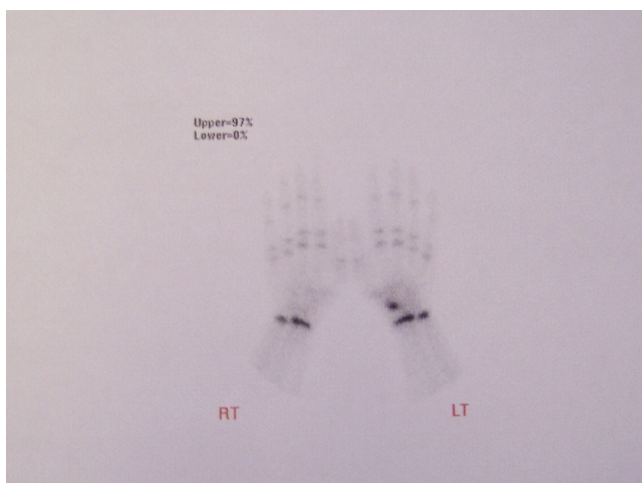


Which nerves would need to be blocked to reduce this injury under local anaesthetic?

(2)

Radial and median nerves

What does this picture show? (1)



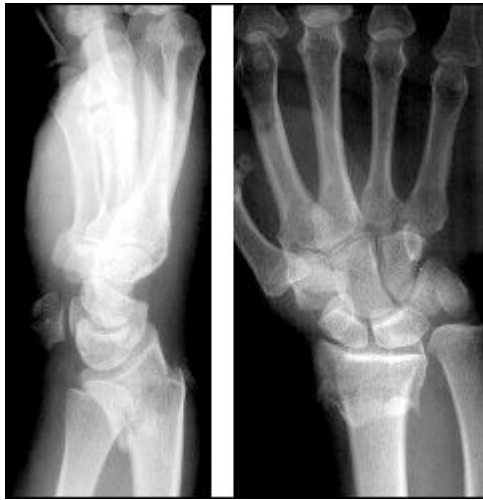Bone scan of wrist showing increased uptake in left scaphoid region

What are the complications of this injury (2)

Avascular necrosis of proximal pole of scaphoid

Non union and Sudek's Atrophy/ RSD/Chronic regional pain syndrome

Describe the x ray below. (2)



There is a fracture of the distal radius.(1)

There is shortening and palmar/anterior angulation (1)

Smiths Fracture (1)

-1 for colles!!!

How would you manage this patient? (1)

Analgesia

Backslab POP

Refer orthopaedics. Unstable injury

½ each