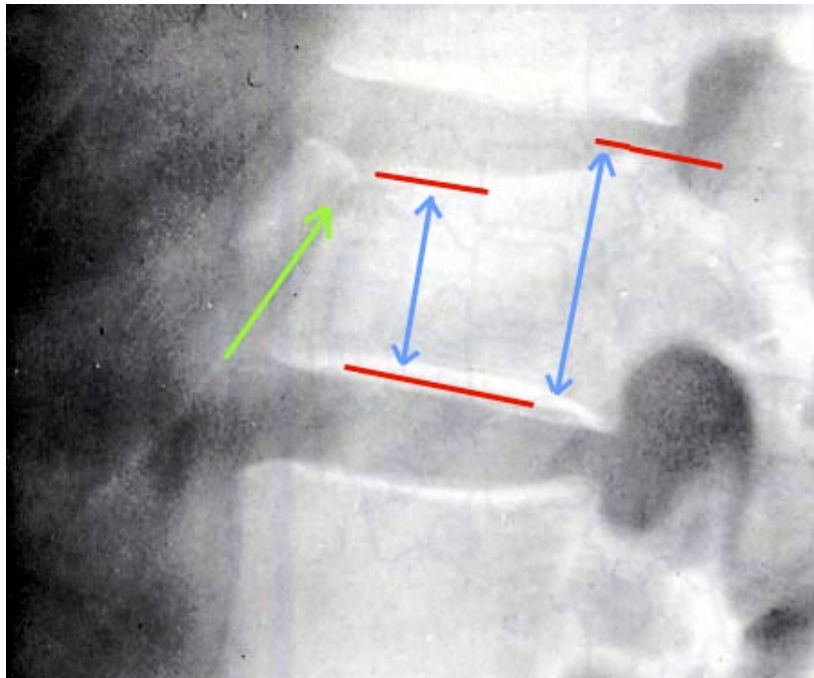


A 27 year old male has fallen onto his buttocks from a height of 4 m whilst skateboarding at a local ramp. He complains of severe back pain. The lateral view of L3 is shown below



a) Describe the myotomes and dermatomes below (4 marks)

	Dermatome	Myotome
L3	<i>Anterior thigh</i>	<i>Hip extension Knee flexion</i>
L4	<i>Ant thigh, ant knee Medial foot</i>	<i>Knee extension Foot dorsiflexion</i>

b) What features of a similar injury would lead you to suspect it was unstable? (4 marks)

*anterior margin < 1/2 posterior margin (posterior complex rupture)  
avulsion fracture at tip of spinous process  
wide separation of vertebral spines at level of injury  
facet joint or pedicle fracture  
facet joint dislocation*

c) At what stage should he be removed from the Spine board? (1 Mark)  
*as soon as possible*

d) What other injuries are associated with this injury? (1 Mark)  
*other spinal injuries, base of skull fracture*