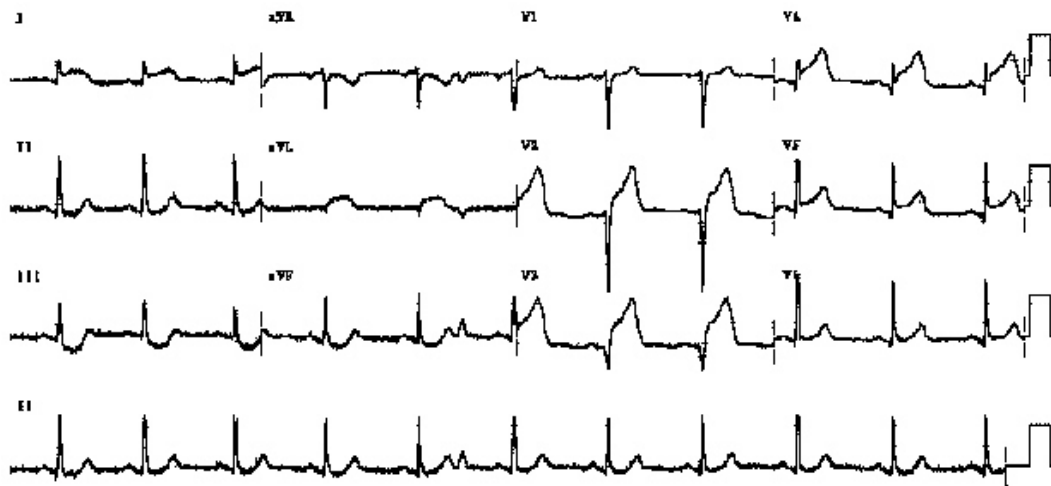


Chest pain thrombolysis

A 58 yr old man attends your department with 50 mins of central crushing chest pain. He was previously well. His ECG is this



Describe this ECG (3 marks)

Sinus Rhythm. Normal axis. ST elevation in I and V2 - V4 with reciprocal ST depression in II and III

What is the diagnosis? 1 mark

Anterior Myocardial infarction

What are the criteria for thrombolysis? (1 marks)

*1 mm ST elevation in 2 contiguous limb leads
2 mm ST elevation in 2 contiguous chest leads
New onset LBBB*

What are the absolute contraindications to thrombolysis (5 marks)?

*Thrombotic stroke 2/12
Intracranial bleed
Head injury 2/12
Surgery/Trauma 2/12
Other bleed 1/12
Pregnant/recent delivery
Aortic Dissection*